



Medical Case Reports Journal

Available Online: <http://mcrj.edwiserinternational.com>

Proteus Syndrome in Intensive Care Unit: Case Report and Review of the Literature

Ebru Tarıkçı Kılıç^{1*}, Mehmet Salim Akdemir¹, Mustafa Deniz Dinkçi¹, Egemen Atağ¹ and Onur Gürsu¹

¹Department of Anesthesiology, Ümraniye Research Hospital, Health Sciences University, Turkey

Article info

Received 05 March 2018

Revised 07 April 2018

Published 13 April 2018

*Corresponding author: Ebru Tarıkçı Kılıç, Department of Anesthesiology, Ümraniye Research Hospital, Health Sciences University, Turkey; E-mail: Ebru.tarkc@yahoo.com

Abstract

Proteus syndrome (PS) a complex disorder is rare with multisystem involvement. An extremely rare condition characterized by macrodactyly, vertebral abnormalities, asymmetric limb overgrowth and length discrepancy, hyperostosis, abnormal and asymmetric fat distribution, asymmetric muscle development, connective tissue nevi, and vascular malformations. It is progressive. Asymmetrical limb overgrowth is mostly seen and pathognomic. Patients have an unusual body habitus. The diagnosis may be delayed until late infancy because cutaneous lesions tend to appear over time, childhood, or even adulthood. We report a 16 years old boy who admitted to Intensive Care Unit (ICU) due to the arteriovenous malformation.

Keywords: *Proteus syndrome, Cutaneous lesions, ICU, Arteriovenous malformation.*

Introduction

Proteus syndrome, polymorphism was first described by Cohen and Hayden in 1979 with an estimated prevalence of <1/1000000 live births [1]. It is a hamartoneoplastic disorder taken its name Proteus of the Greek God of the sea who had the ability to change his shape to avoid capture. Partial gigantism of the hands, feet, asymmetry of the arms, legs, macrocephaly, epidermal naevi, varicosities, plantar hyperplasia, hypertrophy of long bones are the most common skeletal deformities [2]. The basic reason is the overgrowth of cells in skin, bone and connective tissues [3]. Due to the variable features the diagnosis is difficult for clinicians. Prognosis is not clear, patients must be followed up for the risks of neoplasms.

Case Presentation

A 16 years old boy with normal intelligence diagnosed with PS referred to our emergency department unit with his family due to the loss of consciousness with impairment of the reflexes. To maintain the airway, he was intubated urgently and transferred to the internal

care unit. He was mechanically ventilated with synchronized intermittent mandatory ventilation (SIMV) and pressure support (PS) ventilation with a Datex Ohmeda ventilator, tidal volume 450 ml, pressure support (PS): 15 mm Hg peep 5 under sedation. On physical examination, we noted facial asymmetry hyperpigmented skin, multiple hemangiomas, epidermal nevi on the back of his neck, on his chest, on the right leg. Airway assessment showed mallampati grade 2, misaligned teeth, high arched palate. Laboratory investigations revealed normal renal and liver function tests. The chest X-Ray and other skeletal survey were normal. There is no history of similar illness in his family.

After connecting all monitors and securing the intravenous access sedation was started in order to carefully treat to reduce the risk of hematoma expansion and to keep and maintain cerebral perfusion pressure (CPP; CPP=mean arterial pressure (MAP)-ICP) we started propofol (propofol 0.15 mg/kg/h) and dexmedetomidine (0.2 mcg/kg/h) infusion. Within two

days he was successfully weaned off and extubated. Neurosurgeons ordered conventional diagnostic cerebral angiography to see the arteriovenous malformations. For further evaluation the patient was taken to angiography unit with 3 l/min nasal O₂. Propofol 3 mg/kg/h infusion with remifentanyl was used to sedate the patient during brain angiography. No complications occurred during the procedure. Angiography was lasted for 30 minutes and the patient was taken to the ICU unit again for hemodynamic monitoring. A week later he was discharged to the neurosurgery ward with Glasgow coma scale 15.

Discussion

In PS asymmetric hyperplasia of tonsils, adenoids, facial asymmetries, tongue hemangiomas usually occur and can cause airway obstruction. Affected patients often need orthopedic or reconstructive plastic surgeries for physical rehabilitation. The musculoskeletal and soft tissue growth may lead to airway management problems and regional anesthesia problems [4]. Airway and skeletal problems are challenging for anesthesiologists. In this case we didn't have any problems in intubation as mallampati score was grade 2 (Figures 1-3).

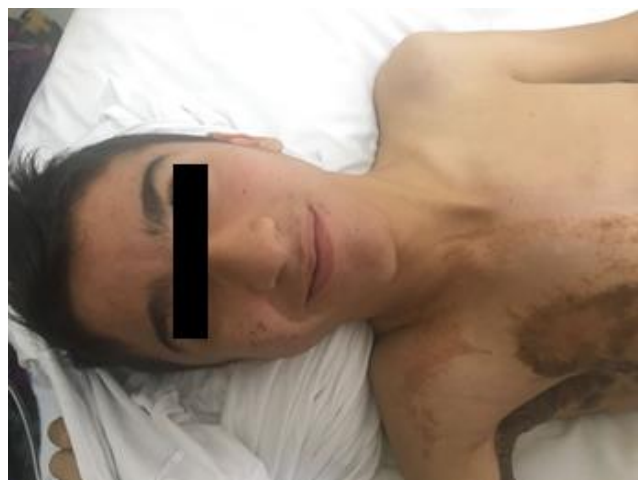

Figure 1: Epidermal nevi and facial asymmetry.

Asymmetrical vertebra, kyphosis, scoliosis are the difficulties for central blocks. Skeletal hypertrophy and overgrowth add difficulties in positioning the patients. Vascular malformations in PS predispose patients to intracranial hemorrhage as in our case. 200 cases have been reported up to now, but none has been associated with intracranial hemorrhage due to the AVM malformation. Primary involvement of lung diseases, kyphoscoliosis causing secondary restrictive lung diseases are the reasons of perioperative respiratory failure [5,6].

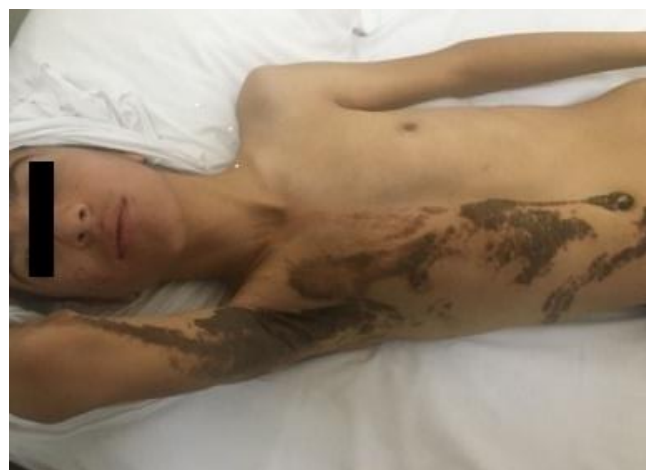

Figure 2: Epidermal nevi on chest.

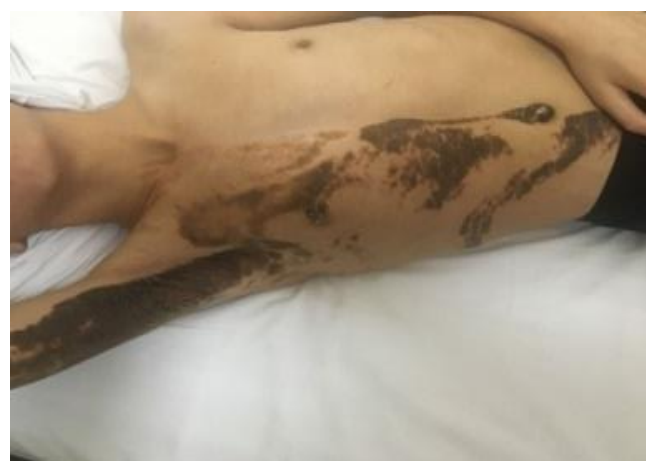

Figure 3: Skin lesions on chest.

Lung diseases lead to repeated pneumonias, atelectasis. Poor respiratory system can cause respiratory failure. Preoperative pulmonary function tests can be done. Hypertrophic cardiac rhabdomyomas is rare but always to be on mind (Figures 4 and 5).

For orthopedic surgeries regional anesthesia can be preferred. Besides regional anesthesia has analgesic advantages. Anatomical abnormalities cause technical difficulties in intubation. Pennant and friends provided general anesthesia to a 14 years old boy with fiber-optic bronchoscope for difficult airway who was scheduled for corrective orthopedic surgery. In another case presentation Sinha managed the airway control with Mc Coy laryngoscope. Pradhan described a case of difficult intubation of a 7 years old boy with PS having teeth malocclusion, high arched palate, inspiratory stridor with Mc coy laryngoscope [7].

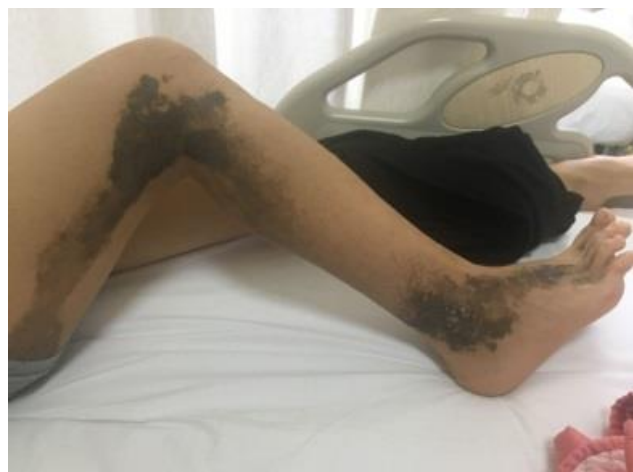

Figure 4: Skin lesions on right leg.

Ambu LMA can be also used in case of airway rescue. It is an alternative technique to be on mind and avoids critical attempts in case of difficult intubation.

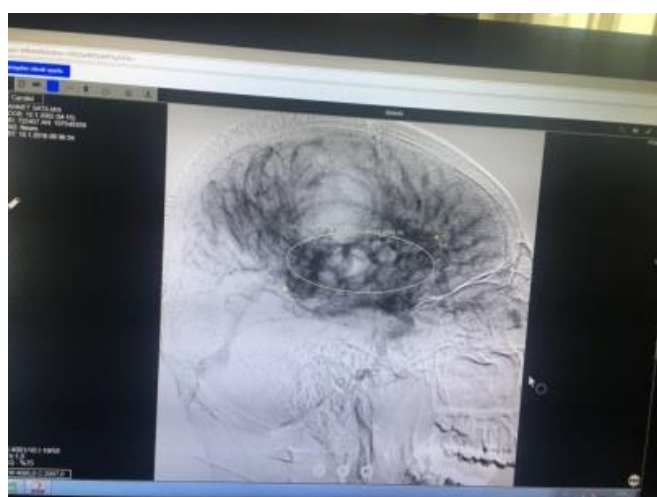


Figure 5: AVM malformation on angiogram.

For the patients diagnosed with Proteus syndrome treatments differ due to the medical needs. Geneticist, pediatrician (for children) or internist (for adults)

coordinate the medical care. Rarely, as in our case Proteus syndrome requires aggressive treatment. Before a treatment decision is made Proteus syndrome may be monitored over a period of time. Orthopedic surgeon, dermatologist, physiatrist, pulmonologist, occupational therapist and a pedorthist should be involved in treatment of Proteus syndrome patients.

Conflict of Interest

None declared.

Funding

None declared.

References

1. Cohen MM Jr. Proteus syndrome review: Molecular, clinical, and pathologic features. *Clin Genet* 2014; 85: 111-119.
2. Bastos H, da Silva PF, de Albuquerque MA, et al. Proteus syndrome associated with hemimegalencephaly and ohtahara syndrome: Report of two cases. *Seizure* 2008; 17: 378-382.
3. Lindhurst MJ, Sapp JC, Teer JK, et al. A mosaic activating mutation in AKT1 associated with the proteus syndrome. *N Engl J Med* 2011; 365: 611-619.
4. Darling NT, Bisecker GL. Progressive overgrowth of the cerebriform connective tissue nevus in patients whit proteus syndrome. *J Am Acad Dermatol* 2010; 63: 799-804.
5. Mirastschijski U, Altmann S, Lenz-Scharf O, et al. Syndromes with focal overgrowth in infancy: Diagnostic approach and surgical treatment. *J Plast Surg Hand Surg* 2012; 46: 45-48.
6. Neylon OM, Werther GA, Sabin MA. Overgrowth syndromes. *Curr Opin Pediatr* 2012; 24: 505-511.
7. Caux F, Plauchu H, Chibon F, et al. Segmental overgrowth, lipomatosis, arteriovenous malformation and epidermal nevus (SOLAMEN) syndrome is related to mosaic PTEN nullizygosity. *Eur J Hum Genet.* 2007; 15: 767-773.

This manuscript was peer-reviewed
Mode of Review: Single-blinded
Academic Editor: Dr. Ruqaiyah Saleem