



Successful Use of Fluoroscopic Inlet and Outlet Views to Verify Safe Screw Trajectories when Placing Percutaneous Iliosacral Screws

Jae Man Kwak¹, Sung-Keun Heo² and Gu-Hee Jung^{3*}

¹Department of Orthopaedic Surgery, Asan Medical Center, University of Ulsan, Seoul, Republic of Korea

²Department of Orthopaedic Surgery, Gi-Jang Hospital, Busan, Republic of Korea

³Department of Orthopaedic Surgery, College of Medicine, Gyeongsang National University Changwon Hospital, Republic of Korea

Article info

Received 19 February 2018

Revised 13 March 2018

Published 22 March 2018

*Corresponding author: Gu-Hee Jung, Department of Orthopaedic Surgery, College of Medicine, Gyeongsang National University Changwon Hospital; Tel: +82-55-214-3822;

E-mail: jyujin2001@hotmail.com

Abstract

Purpose: The purpose of this study was to introduce practical landmarks for the successful use of the fluoroscopic inlet and outlet views to verify safe screw trajectories when placing percutaneous iliosacral (IS) screws.

Materials and Methods: A total of 10 sacra (19 hemi-sacra) from cadavers without gross deformity or previous injury were included in this study. The upper boundaries and S1 were marked with 1 mm lead wire. The marked sacra were positioned on a radiolucent operative table similar to the operative supine position and projected into the pelvic inlet and outlet views and the true lateral view of the pelvis via an image intensifier. Using image editing software, fluoroscopic images were analyzed to identify the fluoroscopic landmarks and ideal entry points.

Results: The posterior-superior corner of the lateral articular surface was constantly projected as a curve point in the pelvic inlet view, and the imaginary connecting line between two points did not violate the posterior walls of S1 in any of the sacra with a little space. Based on the curve points, screws had to be directed either straight or anteriorly (range: 18.3°-29.6°) on inlet view. On outlet view, the ideal screw trajectory was the imaginary oblique line from the height of the S1 foramen to the opposite upper corner of S1 (range: 15.5°-24.4°) and the sacral ala was not violated.

Conclusion: For successful fluoroscopy, two simple landmarks could be utilized, the imaginary connecting line between the two curve points in the pelvic inlet view and the oblique screw trajectory toward the opposite corner of S1 in the pelvic outlet view, using the standard technique and irrespective of sacral dysplasia.

Keywords: Pelvis, Iliosacral screw fixation, Fluoroscopic landmark, Entry point

Introduction

Although iliosacral (IS) screw fixation has been widely used owing to biomechanical advantages, the technique is demanding because of the site's three-dimensional anatomical complexity, being close to neurovascular structures and having frequent upper sacral

morphological variations [1-3]. Although the reported preoperative and intraoperative techniques [4-6] may aid in IS screw insertion, they require additional software for imaging and data analysis. Separately, although a safe and sufficient corridor for screw

placement was also identified using preoperative planning [7-9], there is still the possibility of extra-osseous screw placement because of misinterpreted fluoroscopic imaging or incorrect technical execution [10,11].

With regard to the obscurity of fluoroscopic images, which contributes to their misinterpretation, a number of conditions make it difficult during fluoroscopically guided surgery to clearly visualize safe corridors for ideal IS screw placement, including bowel gas, obesity, and sacral dysplasia. Because there were also disparities in standard fluoroscopic images based on individual variations in pelvic tilt or the lumbosacral junction, Eastman et al. [7] reported the usefulness of appropriate planning for anticipated intraoperative fluoroscopic inlet and outlet views by measuring preoperative CT sagittal reconstruction images. However, those authors also noted that these predetermined angles could be less reliable in clinical practice because they were influenced by the patient's position and the accurate interpretation of images [7].

In addition, although preoperative planning could verify sufficient bone corridors, screws could be placed eccentric to the ideal or planned locations, and thus, most surgeons preferred intraoperative implementation by fluoroscopic landmarks that were easily visualized by standard techniques and enabled surgeons to control the screw trajectory in real time. Surgical techniques have now changed based on improved understanding of posterior pelvic radiographic anatomy to enable clearer visualization of safe corridors during fluoroscopically guided IS screw placement [5,7,12]. In this study, we introduce relevant landmarks for the successful use of the fluoroscopic inlet and outlet views to verify safe screw trajectories when placing percutaneous IS screws.

Materials and Methods

This study design received institutional review board approval. We included ten dried sacra (19 hemi-sacra) without previous injury or visible deformity; the ages and sexes of the patients from whom the samples were collected were unknown; we excluded one hemi-sacrum because of a dirty, obscure margin associated with poor storage in the cadaveric laboratory. To make the margins clearly visible on the standard fluoroscopic views, we marked the border between the upper boundary and the first sacral segment (S1) with 1 mm lead wire on each sacrum (Figure 1). We placed each marked sacrum on the radiolucent operation table similar to the operative supine position and maintained this position to give the same image intensification ratio throughout the experiments. We performed the

fluoroscopic imaging with Varic® (Siemens, Munich, Germany) using the pelvic inlet, outlet, and true lateral views, which are the standard views for verifying IS screw positioning [11].

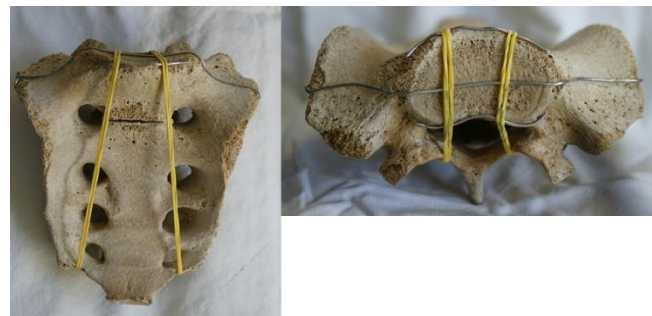

Figure 1: Upper boundary and S1 were marked with 1 mm lead wire to create a clearly visible margin under the image intensifier.

We defined the ideal fluoroscopic inlet view as the precise overlap of the anterior cortex of S1 on the anterior cortex of the second sacral body (S2) [11,12]. The ideal outlet view was the pubic symphysis overlying the midline of the sacrum and the round sacral foramen, and the ideal true lateral view was the precise overlap of the lateral articular surfaces [11,12]. Once images of acceptable or good quality were taken, we processed the raw anonymized fluoroscopy DICOM (digital imaging and communication in medicine) files into JPEG files using PACS software (Infinit Healthcare, Seoul, Korea). We defined the safe zone as a screw's containment within the bony confines of the S1 ala and S1 to prevent injury to adjacent neurovascular structures from extra-osseous screw placement [13,14]. Another stipulation was that the end of the IS screw should be located over the midline of S1. Using the pelvic outlet view, we compared the top of the sacral alar slope with the upper border of the lateral surface [1,3]. The hemi-sacrum was described as positive (+) if the top of the ala was superior to the upper border of the lateral surface and negative (-) if it was inferior (Figure 2A). Considering the alar slope and the S1 foramen, we determined the upper and lower limits of the safe zone.

In the pelvic outlet view, we chose the superior-posterior border of the lateral articular surface as a reference point because it could be easily visualized without additional procedure (Figure 2B). In the pelvic inlet view, we determined the anterior and posterior limits of the safe zone considering the spinal canal and anterior cortical indentation of the ala (Figure 2B). We measured the angles of the safe zones in the inlet and outlet views using the extracted JPEG images of the

marked sacra with Adobe Photoshop CS6® image editing software (San Jose, CA, USA). All measurements are presented as degrees (°).

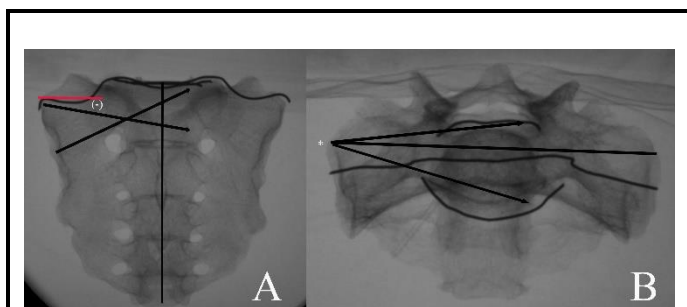


Figure 2: (A) Fluoroscopic outlet projection view was used to measure the safe range of IS screws from inferior to superior by considering the sacral ala and S1 foramen; it was described as positive (+) if the top of the sacral ala was superior to the upper border of the lateral surface and as (-) if the top was inferior to it. (B) The superior-posterior border of the lateral articular surface* was chosen as a reference point in pelvic inlet view. The anterior and posterior limits of the safe zone were determined considering the spinal canal and anterior cortical indentation of the ala.

Results

Grossly, the posterior borders of the S1 bodies had two shapes: concave (two sacra) and round (eight sacra); the lateral articular surfaces of the sacra resembled commas but changed to oval shapes depending on the sizes and widths of the pedicles (Figure 3A). The posterior wall of S1 was nearly aligned with the posterior margin of the superior border in the lateral articular surface (Figure 3B). The posterior-superior corner of the lateral articular surface was constantly projected as a curve point in the fluoroscopic inlet view (Figure 3C).

In the pelvic inlet view, due to the obliquity of fluoroscopic projection, the posterior wall of S1 was placed over the spinal canal as expected. However, the posterior wall of the first sacral segment that overlapped with the spinal canal was much larger than expected. When drawn between two curve points, the imaginary connecting line did not violate the posterior wall of S1 in any of the sacra with a little space. Based on the imaginary connecting line in the pelvic inlet view, the safe range averaged from 3.7° (range: 1.4°-7.8°) posteriorly to 24.4° (range: 18.3°-29.6°) anteriorly. To avoid violating the spinal canal and anterior cortex of the sacral ala and body, the screw direction should be straight or anterior (less than 18.3°).

In the pelvic outlet view, fourteen hemi-sacra had (-) values, and the angle between the superior margin of the

articular surface and the top of the sacral ala was on average -0.2° (range: -12.4°-19.3°). Considering the alar angle and the S1 foramen in the pelvic outlet view, the ranges for safe IS screw placement were means of -5.9° (range: -19.6°-7.5°) inferiorly based on the superior pole of the lateral articular surface and of 19.9° (range: 15.5°-24.4°) superiorly based on the horizontal extension line of the S1 foramen. When screw trajectory was started at the height of the S1 foramen and obliquely directed toward the opposite upper corner of S1, there was no violated sacral alar cortex regardless of sacral variations. Based on the fluoroscopic landmarks including the curve point in the inlet view and the horizontal extension line of the S1 foramen in the outlet view, we were able to propose a convenient entry point and trajectory for full intraosseous placement of IS screws.

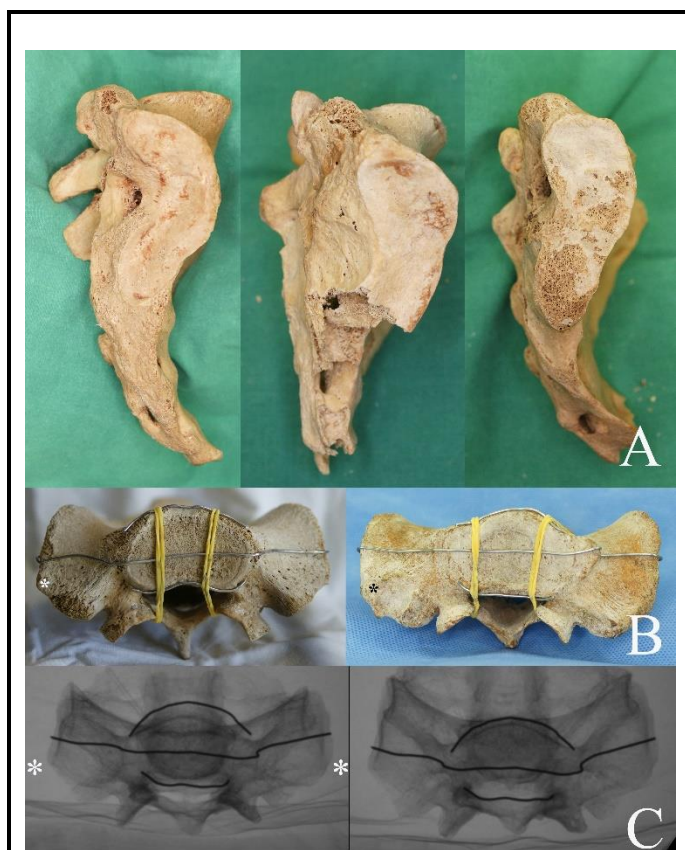


Figure 3: (A) The lateral articular surface of the sacrum resembled a comma and changed to an oval shape depending on the size and width of the pedicle. (B) There are two shapes of the posterior borders of S1 bodies, concave and round, and the posterior wall of S1 was nearly aligned with the posterior margin of the superior border on the lateral articular surface. The posterior-superior corner* of the lateral articular surface was constantly projected as a curve point in pelvic inlet view.

Discussion

Although many techniques and relevant landmarks for fluoroscopically guided IS screw fixation have been reported in previous studies [2,4,9,12,14,15], technical errors resulting in malposition-related complications are still occurring. As we have gained experience with this procedure, we have felt that fluoroscopic landmark images could be utilized intraoperatively to verify safe screw trajectories in real time in standard fluoroscopic views.

Through this cadaveric study, thus, we introduced two practical landmarks that can be easily visualized without additional support: (1) We used the imaginary connecting line between two curve points to guide the safe screw trajectory as the posterior limit to prevent the posterior cortical violation of S1 in the pelvic inlet view, and (2) the IS screw always had a safe path in the osseous corridor if the direction was from the height of the S1 foramen to the opposite upper corner of S1 in the pelvic outlet view regardless of sacral dysplasia. Unless a transiliac-transsacral screw is required, such as with central sacral fractures or bilateral injuries [9,16-19], our screw trajectory guided by fluoroscopic landmarks might help to overcome sacral dysplasia and create a safe corridor for the entire length.

Despite many well-known anatomic landmarks, the suboptimal views by mal-rotation of the image intensifier have been shown to affect the safe placement of IS screws [7,11]. Concerning the cortical violation of the posterior wall of S1, Wolinsky et al. [11] demonstrated that when the X-ray tube is rotated $>8^\circ$ toward the foot away from the ideal inlet view, the K-wire placed into the sacral canal can appear to be contained within the bony sacrum. Through this study, we identified that the superior-posterior corner of the sacrum's lateral articular surface was nearly aligned with the posterior wall in all sacra and was constantly projected as a curve point in the standard inlet view (Figure 3C).

Furthermore, the imaginary connecting line between two curve points could be used for the posterior limit of the safe screw trajectory to prevent violating the cortex of the posterior wall without regard for moving the X-ray tube from a perfect position. The computational simulation of IS screw fixation also demonstrated that an improper cant of the inlet view might not affect the utility of the imaginary connecting line for verifying the cortical violation of S1 (Figure 4). To prevent violating the sacral ala cortex, the screw should be started from the curve point or just anterior to it and directed at a straight or slightly anterior (less than 18°) angle based

on our results. By basing the entry point and trajectory on the curve point in the pelvic inlet view, the IS screw's placement in S1 could be guaranteed as fully intraosseous, which would prevent a malpositioned screw from exiting the ilium anterior to the sacral ala and reentering the sacral body [3,11].

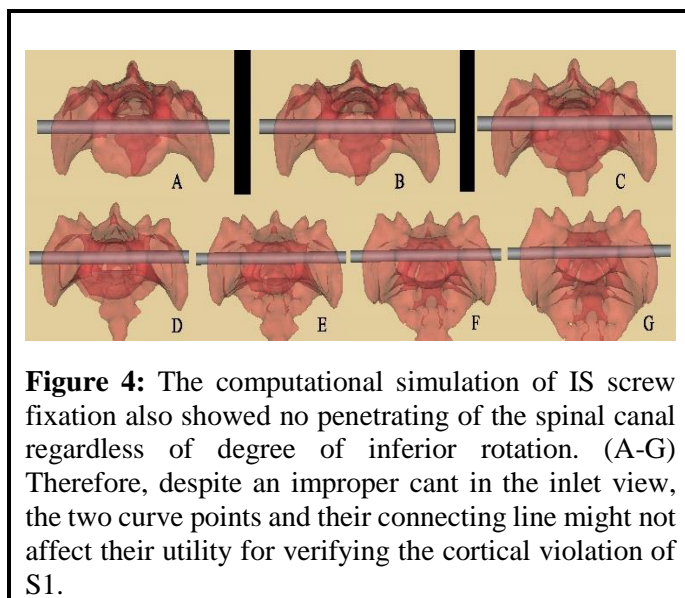


Figure 4: The computational simulation of IS screw fixation also showed no penetrating of the spinal canal regardless of degree of inferior rotation. (A-G) Therefore, despite an improper cant in the inlet view, the two curve points and their connecting line might not affect their utility for verifying the cortical violation of S1.

In the pelvic outlet view, the entry point must be chosen by considering the S1 foramen and alar angle that were related to the sacral dysplasia. Because the superior portion of the S1 foramen is the easiest structure to identify in the outlet view, it could be used as a landmark and as the inferior osseous boundary of the volume of bone used for screw placement [20]. By marking the border of the upper boundary and S1 with a 1 mm lead, we also found the S1 foramen useful for determining consistent and safe screw trajectories, which started at the height of the S1 foramen and were obliquely directed toward the opposite upper corner of S1.

Although the possibility of transverse fixation could not be provided, our results might help with determining the degree of screw obliquity and guaranteeing the intraosseous placement. Therefore, if the IS screw cannot be placed transversely by preoperative verification [9] and a transiliac-transsacral screw is not mandatory, our proposed screw entry point and trajectory can be used easily with standard inlet and outlet views.

Thus, considering the fluoroscopic landmarks the opposite upper corner of the S1 body in the outlet view and the opposite curve point in the inlet view the concept of "tip-to-apex distance" (TAD) in the lag screw fixation of proximal femoral fracture is likely to be applied to prevent cortical violation and predict the

intraosseous placement along the entire path. For safe and consistent placement of IS screws in S1, our two landmarks might be useful as the target tips in the TAD, and the ends of the screws should be closest to these tips to minimize the distance (Figure 5).

The clinical usefulness of this study differs from that of previous cadaveric studies [1,11,12,21,22] in a number of respects. As mentioned before, we introduced easy and convenient landmarks using standard views and irrespective of any improper canting of the X-ray tube or of sacral dysplasia.

In addition, based on the real-time images, which differed from the original inlet and outlet radiographs and CT scans [5,6,12,23], we could use these landmarks intraoperatively to control the screw trajectory and length because we set the ideal target points, the opposite curve point and the upper corner of S1, to achieve a fully intraosseous position along the entire path (Figure 6).

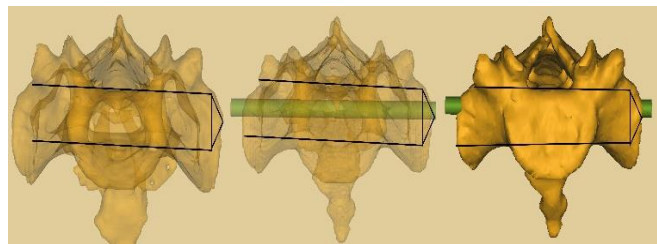


Figure 5: For precise and consistent placement of IS screws in S1, our two landmarks might be useful as the target tips in the TAD (Tip-to-Apex distance). The end of the screw should be close to prevent the cortical violation and predict the intraosseous placement along the entire path.

Although the lateral pelvic view has been accepted as a key view and has been recommended to determine the starting point on the outer ilium, it is difficult to obtain and interpret [20,24] because there is inevitable overlap between the operator's hand and the instruments.

In this study, however, by mostly using the inlet and outlet views to safely place the IS screws, we could prevent not only the overlap but also the radiation exposure to the operator's hand, which are both common in the pelvis lateral view (Figure 6).

Despite these simple and interesting findings, our study has a number of fundamental limitations. First, because all the sacra were dried, the sacrum in a living person might be different, and we could not consider the possibility of variance depending on gender, ethnicity, age, or numbers of affected sacra. Second, our results

may only be useful in anatomically reduced fractures without comminution or free fragments around the sacro-iliac joint, and they are more descriptive in character compared with the findings from existing studies.

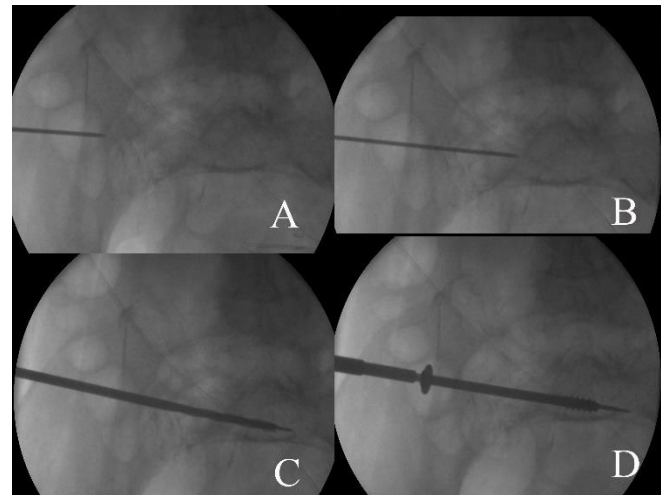


Figure 6: (A) The curve point was easily identified by standard fluoroscopic inlet view. (B-D) The direction of the guide wire and screw could be controlled and checked in real time.

Most important, the curve point as key landmark might sometimes be difficult to identify in practical situations. Nevertheless, this investigation provides significant implications for IS screw fixation: (1) The imaginary connecting line between two curve points in the fluoroscopic inlet view could be used as the posterior limit for safe placement and (2) oblique and consistent screw trajectories could be made at the height of the S1 foramen and directed toward the opposite upper corner of S1. In future, our landmarks need to be confirmed in clinical series.

Conclusion

For successful fluoroscopy to verify the intra-osseous placement of IS screws, two simple landmarks, the imaginary connecting line between two curve points in the pelvic inlet view and an oblique screw trajectory toward the opposite corner of S1 in the pelvic outlet view can be utilized with standard fluoroscopic techniques.

These landmark-assisted fixation techniques determine the degree of screw obliquity and guarantee intraosseous placement along the entire path regardless of sacral dysplasia and allow for real-time control of screw trajectory without additional procedure.

Authors' Contribution

GH designed and control all the process for this study and performed the surgery. JM collected information related with the study as the main drafter. SK participated in its design and coordination and helped to collect information. All authors read and approved the final manuscript.

Conflict of Interest

None declared.

Funding

None declared.

References

1. Conflitti JM, Graves ML, Chip Routh ML Jr. Radiographic quantification and analysis of dysmorphic upper sacral osseous anatomy and associated iliosacral screw insertions. *J Orthop Trauma* 2010; 24: 630-636.
2. Ebraheim NA, Xu R, Biyani A, et al. Morphologic considerations of the first sacral pedicle for iliosacral screw placement. *Spine (Phila Pa 1976)* 1997; 22: 841-846.
3. Routh ML Jr., Simonian PT, Agnew SG, et al. Radiographic recognition of the sacral alar slope for optimal placement of iliosacral screws: A cadaveric and clinical study. *J Orthop Trauma* 1996; 10: 171-177.
4. Mendel T, Radetzki F, Wohlrab D, et al. CT-based 3-D visualisation of secure bone corridors and optimal trajectories for sacroiliac screws. *Injury* 2013; 44: 957-963.
5. Alemdaroglu KB, Yucens M, Kara T, et al. Pedicle axis view combined by sacral mapping can decrease fluoroscopic shot count in percutaneous iliosacral screw placement. *Injury* 2014; 45: 1921-1927.
6. McAndrew CM, Merriman DJ, Gardner MJ, et al. Standardized posterior pelvic imaging: Use of CT inlet and CT outlet for evaluation and management of pelvic ring injuries. *J Orthop Trauma* 2014; 28: 665-673.
7. Eastman JG, Routh ML Jr. Correlating preoperative imaging with intraoperative fluoroscopy in iliosacral screw placement. *J Orthop Traumatol* 2015; 16: 309-316.
8. Lucas JF, Chip Routh ML Jr., Eastman JG. A useful preoperative planning technique for transiliac-transsacral screws. *J Orthop Trauma* 2016.
9. Mendel T, Noser H, Wohlrab D, et al. The lateral sacral triangle: A decision support for secure transverse sacroiliac screw insertion. *Injury* 2011; 42: 1164-1170.
10. Sagi HC, Lindvall EM. Inadvertent intraforaminal iliosacral screw placement despite apparent appropriate positioning on intraoperative fluoroscopy. *J Orthop Trauma* 2005; 19: 130-133.
11. Wolinsky P, Lee M. The effect of C-arm malrotation on iliosacral screw placement. *J Orthop Trauma* 2007; 21: 427-434.
12. Ozmeric A, Yucens M, Gultac E, et al. Are two different projections of the inlet view necessary for the percutaneous placement of iliosacral screws? *Bone Joint J* 2015; 97-B: 705-710.
13. Day CS, Prayson MJ, Shuler TE, et al. Transsacral versus modified pelvic landmarks for percutaneous iliosacral screw placement: A computed tomographic analysis and cadaveric study. *Am J Orthop (Belle Mead NJ)* 2000; 29: 16-21.
14. Carlson DA, Scheid DK, Maar DC, et al. Safe placement of S1 and S2 iliosacral screws: the "vestibule" concept. *J Orthop Trauma* 2000; 14: 264-269.
15. Noojin FK, Malkani AL, Haikal L, et al. Cross-sectional geometry of the sacral ala for safe insertion of iliosacral lag screws: A computed tomography model. *J Orthop Trauma* 2000; 14: 31-35.
16. Vanderschot P, Meuleman C, Lefevre A, et al. Trans iliac-sacral-iliac bar stabilisation to treat bilateral lesions of the sacro-iliac joint or sacrum: Anatomical considerations and clinical experience. *Injury* 2001; 32: 587-592.
17. Gardner MJ, Routh ML Jr. Transiliac-transsacral screws for posterior pelvic stabilization. *J Orthop Trauma* 2011; 25: 378-384.
18. Heydemann J, Hartline B, Gibson ME, et al. Do transsacral-transiliac screws across uninjured sacroiliac joints affect pain and functional outcomes in trauma patients? *Clin Orthop Relat Res* 2016; 474: 1417-1421.
19. Zhao Y, Li J, Wang D, et al. Comparison of stability of two kinds of sacro-iliac screws in the fixation of bilateral sacral fractures in a finite element model. *Injury* 2012; 43: 490-494.
20. Ziran BH, Wasan AD, Marks DM, et al. Fluoroscopic imaging guides of the posterior pelvis pertaining to iliosacral screw placement. *J Trauma* 2007; 62: 347-356.
21. Gardner MJ, Morshed S, Nork SE, et al. Quantification of the upper and second sacral segment safe zones in normal and dysmorphic sacra. *J Orthop Trauma* 2010; 24: 622-629.
22. Liu J, Li Y, Wu Y, et al. An anatomic study on the placement of the second sacral screw and its clinical

Citation: Kwak JM, Heo SK, Jung GH. Successful Use of Fluoroscopic Inlet and Outlet Views to Verify Safe Screw Trajectories when Placing Percutaneous Iliosacral Screws. *Med Case Rep J* 2018; 1: 103.

- applications. *Arch Orthop Trauma Surg* 2013; 133: 911-920.
23. Graves ML, Routt ML Jr. Iliosacral screw placement: are uniplanar changes realistic based on standard fluoroscopic imaging? *J Trauma* 2011; 71: 204-208.
24. Nork SE, Jones CB, Harding SP, et al. Percutaneous stabilization of U-shaped sacral fractures using iliosacral screws: technique and early results. *J Orthop Trauma* 2001; 15: 238-246.
-

This manuscript was peer-reviewed

Mode of Review: Single-blinded

Academic Editor: Dr. Konstantina Soulele

Copyright: ©2018 Kwak JM, et al. This article is distributed under the terms of the Creative Commons Attribution 4.0 International License (<http://creativecommons.org/licenses/by/4.0/>), which permits unrestricted use, distribution, and reproduction in any medium, provided you give appropriate credit to the original author(s) and the source, provide a link to the Creative Commons license, and indicate if changes were made.

