Medical Case Reports Journal

Available Online: https://mcrj.edwiserinternational.com

Archibald's sign revisited Turners Syndrome in the Fracture clinic: A Case Report

Syed Kashif Mehdi[1,], Talat Mehmood[1] and Paul O'Grady[2]*

[1]Department of Orthopedics, Mayo University Hospital, Ireland
[2]Hon Personal Professor in Surgery, National University of Ireland Galway, Ireland

Article info

Received 20 August 2021
Revised 27 October 2021
Available Online 12 Nov 2021

*Corresponding author:
Dr. Syed Kashif Mehdi, MBBS, BSc, MRCS, FCPS; Department of Orthopedics, Mayo University Hospital, Ireland.

Abstract

A 12-year-old girl was reviewed in orthopaedic clinic after left wrist injury. She was incidentally noted to have a left hypoplastic 4th metacarpal on left wrist and hand radiography. She was otherwise well. She was at 0.6 centile for height (0.4th to 2nd centile) and 9th centile of weight (9th to 25th centile). Speech and hearing were normal. Her mother described her as unusually short for her family. Mother was hypothyroid and managed with thyroxine. This case report provide details of the course of therapy.

Keywords: Turner's Syndrome, Archibald's sign; Fracture; Wrist injury

Introduction

Archibald's Sign was first described in 1959 as the relationship between short fourth metacarpal and gonadal dysgenesis. Since then, short metacarpals have been reported in many different clinical conditions including Turners Syndrome, Pseudo Hypoparathyroidism (PH), Pseudo Pseudo Hypoparathyroidism (PPH), Primary Hypo-parathyroidism and homocyctinuria. Turners' syndrome is one of the most common chromosomal disorders characterized by abnormalities with the X chromosome and phenotypic appearance depending upon the specific genomic deficit. Here we are presenting a case of a young girl who came in our trauma clinic after left wrist injury. She was noticed to have a short fourth metacarpal. Subsequent investigations revealed Turners syndrome.

Case Report

A 12 year old girl was reviewed in Orthopaedic clinic after left wrist injury. She was incidentally noted to have a left hypoplastic 4th metacarpal on left wrist and hand radiography. She was otherwise well. She was at 0.6 centile for height (0.4th to 2nd centile) and 9th centile of weight (9th to 25th centile). Speech and hearing were normal. Her mother described her as unusually short for her family. Mother was Hypothyroid and managed with thyroxine.

On physical examination she had a normal cervical spine, clear lung fields and normal heart sounds. Her Abdominal examination was normal. Metacarpal sign was positive on left hand. She had Breast Tanner stage 1 and pubic hair stage II with scant fair pubic hair and no axillary hair. She had excessively dry skin with one hairy nevus measuring 4cm /1cm below her left knee. There were no obvious neuro-cutaneous abnormalities otherwise.

Her Urea, Electrolytes, Calcium and PTH were normal with Vitamin D level at 58mmol/L. Thyroid profile showed elevated TSH (4.84 mIU/L) with normal free T4 (15.5 pmol/L). FSH and LH also had elevated levels; 161IU/L and 27.4 IU/L respectively. Oestradiol was <100 pmol/L and Progesterone was 0.7 nmol/L. Pelvic Ultrasound and MRI did not show ovary and uterus. Karyotyping showed Mosaic female karyotype with one cell line having monosomy X in 3 cells and 2nd cell line with one X chromosome and one pseudodendritic X chromosome. She had sinus rhythm on ECG and

Echocardiography showed normal aortic arch with no evidence of a bicuspid aortic valve. She had normal biventricular function.

A diagnosis of Mosaic's Turner Syndrome (Mosaic 46X-1 pseudodicentric X Chromosome /45 X) with Primary Gonadal Failure and short stature was made. Treatment was commenced and she was put on Growth Hormone, Thyroxine and Ethinylestradiol.

Patient was followed up regularly and at 2 year review showed Growth velocity of 2.4 cm per 6 months, pubertal tanner stage IV breast development, stage III pubic hair with axillary hair. USG confirmed pubertal Uterus with bilateral ovaries.

Discussion

The relationship of metacarpals with each other was first elaborated by Archibald in 1959 when he described the Metacarpal sign on X-rays of the hand by drawing a line tangentially to the heads of the fourth and fifth metacarpals1. It is positive if it runs through the distal end of third metacarpal rather than passing tangentially distal to its head. Clinically it can be demonstrated by holding a pencil over the ends of the fourth and fifth metacarpals with fully flexed fingers [1] (**Figure 1**).

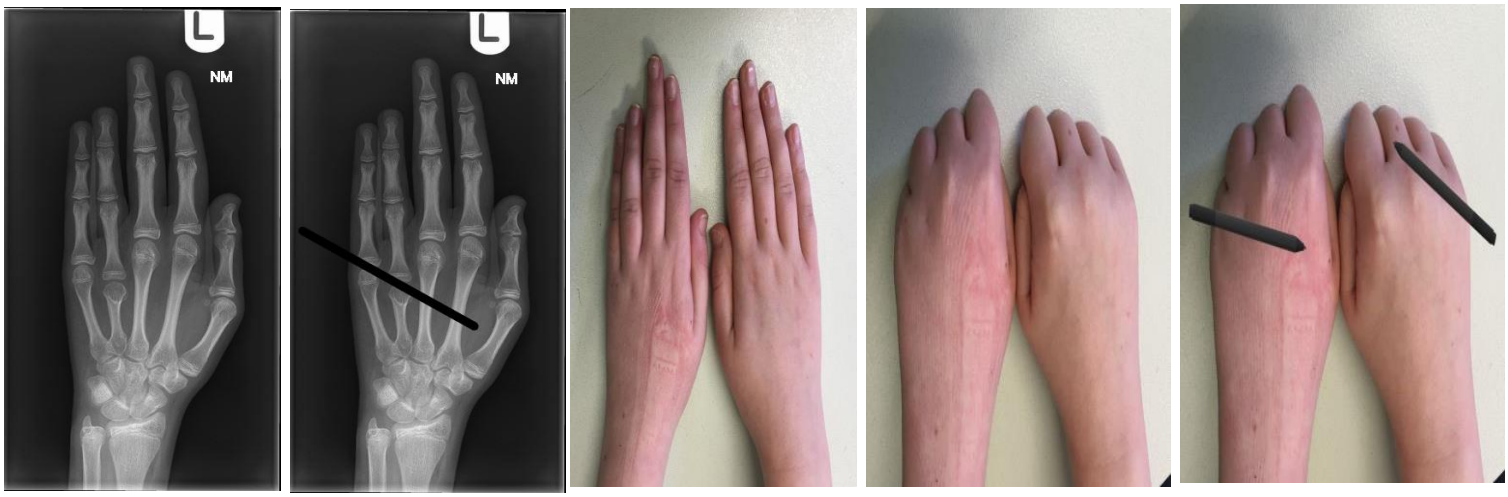

(A) **(B)** **(C)** **(D)** **(E)**

Figure 1: (A) Metacarpal sign (B) Metacarpal sign with line (C) Clinical straight fingers (D) Clinical flexed fingers (E) Clinical flexed fingers with pencil.

Kosowicz et al. described Carpal angle as being formed by intersection of lines touching the scaphoid and lunate bone with the line touching Triquetral and lunate bone [2]. In patients with gonadal dysgenesis this angle was lower than 131.5. Half of gonadal dysgenssis patients with carpal angle less than 117 also have abnormal angular shape of the proximal carpal row described as Positive carpal sign [2]. Some other evaluations like Distal radio-ulnar physeal disparity [3] and phalangeal screening [4] have also been described.

Archibald observed short fourth metacarpal in 2594 outpatients who had gonadal dysgenesis. He also noted that it is more commonly seen in left hand and carries more significance if present in only one generation.

Park E reported the overall incidence of positive metacarpal sign to be 33.8% in Turner's Syndrome [5]. It may normally be present in 9.6% of individuals above the age of 6 years [6]. It may be present in 75 % of the patients with Pseudo Hypoparathyroidism (PH) and in 90% of those with Pseudo Pseudo Hypoparathyroidism PPH [7]. It has also been reported in Primary hypoparathyroidism [8,9] and in homocyctinuria [10].

The overall incidence of Turner Syndrome is approximately 1 in 5000 newborn girls11 and there are two types. Classical form is characterized cytogenetically by X chromosome monosomy [11] whereas Mosaic Turner syndrome has two or more cell lines with different sex chromosome arrangements like 45, X / 46, XX / 46, XY / 47, XXX [11-13]. Phenotypic presentation depends on which part of the X chromosome is missing with latest evidence showing the role of short stature homeobox-containing (SHOX) gene in short stature and various skeletal abnormalities [14].

Conclusion

As German philosopher Immanuel Kant said, the hand is the visible part of the brain. In this case the hand was the visible part of the endocrine System. Turner's syndrome was identified in this young girl on wrist radiograph and timely hormonal treatment resulted in normal development of Ovaries and Uterus. Archibald's Sign is invaluable sign in identifying borderline cases and early presentations.

Funding

None declare.

References

1. Archibald RM, Finby N, Vito FD. Endocrine significance of short metacarpals. J Clin Endocrinol Metab 1959; 19: 1312-1322.
2. Kosowicz J. The carpal sign in gonadal dysgenesis. J Clin Endocrinol Metab 1962; 22: 949-952.
3. Tauber M, Lounis N, Coulet J, et al. Wrist anomalies in Turner syndrome compared with Leri-Weill dyschondrosteosis: A new feature in Turner syndrome. Eur J Pediatr 2004; 163: 475-481.
4. Tiu CM, Liu TC, Hsieh CW, et al. Turner syndrome phalangeal screening based on a two-stage linear regression concept. Pediatr Int 2009; 51: 453-459.
5. Park E. Radiological anthropometry of the hand in Turner's syndrome. Am J Phys Anthropol 1977; 46: 463–470.
6. Slater S. An evaluation of the metacarpal sign (short fourth metacarpal). Pediatrics 1970; 46: 468-471.
7. Steinbach HL, Young DA. The roentgen appearance of pseudohypoparathyroidism (PH) and pseudo-pseudo hypoparathyroidism (PPH). Differentiation from other syndromes associated with short metacarpals, metatarsals, and phalanges. Am J Roentgenol Radium Ther Nucl Med 1966; 97: 49-66.
8. Valizadeh N, Mehdizadeh A, Nazarbaghi S. Short fourth and fifth metacarpals in a case of idiopathic primary hypoparathyroidism. Indian J Endocrinol Metab 2013; 17: 924–926.
9. Ali SS, Amin DM, Majid S, et al. A Rare Case Report of Idiopathic Primary Hypoparathyroidism Coexisting with Shortening of Third to Fifth Metacarpal Bones. Crescent J Medical Biol Sci 2018; 5: 262-264.
10. Tamburrini O, Bartolomeo-De Iuri A, Andria G, et al. Short fourth metacarpal in homocystinuria. Pediatr Radiol 1985; 15: 209-210.
11. Jacobs P, Dalton P, James R, et al. Turner syndrome: A cytogenetic and molecular study. Ann Hum Genet 1997; 61: 471-483.
12. Turnpenny P, Ellard S. Emery's Elements of Medical Genetics. Edinburgh, Scotland: Elsevier Churchill Livingstone 2005: 54-56.
13. Akbas E, Altintas ZM, Celik SK, et al. Rare Types of Turner Syndrome: Clinical Presentation and Cytogenetics in Five Cases. Laboratory Medicine 2012; 43: 97–204.
14. Clement-Jones M, Schiller S, Rao E, et al. The short stature homeobox gene SHOX is involved in skeletal abnormalities in Turner syndrome. Hum Mol Genet 2000; 9: 695-702.

Copyright: ©2021 Mehdi SK, et al. This article is distributed under the terms of the Creative Commons Attribution 4.0 International License (http://creativecommons.org/licenses/by/4.0/), which permits unrestricted use, distribution, and reproduction in any medium, provided you give appropriate credit to the original author(s) and the source, provide a link to the Creative Commons license, and indicate if changes were made.