



Abdomino-Pelvic Impalement Injury: A Case Report

Sandip Kumar Rahul^{1*}, Avinash Kumar², Pankaj Kumar¹, Apurva Agarwal¹ and Sweta¹

¹Department of Paediatric Surgery, Indira Gandhi Institute of Medical Sciences, Patna, Bihar, India

²Department of Surgery, Ruban Hospital, Patna, Bihar, India

Article info

Received 18 March 2018

Revised 30 April 2018

Published 04 May 2018

*Corresponding author: Sandip Kumar Rahul, Department of Paediatric Surgery, Indira Gandhi Institute of Medical Sciences, Patna Bihar, India, Tel: 91-9554464173; E-mail: sandeep.rahul65@gmail.com

Abstract

Abdomino-pelvic impalement injuries are high-risk and present with considerable variations in the nature and extent of organ damage. We describe a case of penetrating injury resulting from fall on three iron rods in a young female. This resulted in multiple bowel perforations and musculoskeletal injuries which were successfully managed. Proper shifting of such patients without disturbing the metal rods is as important as surgical management of their injuries. Also, patients may need anaesthesia in abnormal position to add to the complexity of the situation.

Keywords: Adolescent; Impalement injury; Metal rod.

Introduction

Impalement injuries are rare and have variable presentation depending upon the type of organ involved and the extent of its injury [1]. We present a case of impalement injury in a young female following fall from height and discuss the subtle differences in approach to manage a hemodynamically stable impalement injury patient when compared to an unstable patient.

Case Reports

A 17-year-old female fell from second floor directly over iron rods of an under-construction building at midnight. Although three iron rods penetrated inside her body, she was conscious and oriented but cried in pain. Neighbours cut the rods from the iron pillar with drilling machine and shifted the patient from accident site to the emergency department of our hospital which took 5 hours. During this interval, she was in sitting posture and could not lie down fearing additional trauma due to the penetrating rods. On examination, she was conversant and had a pulse rate of 126/minute and pallor. Two iron rods could be seen penetrating her

abdomen and pelvis while the third one went through and through her gluteal region (Figures 1 and 2).

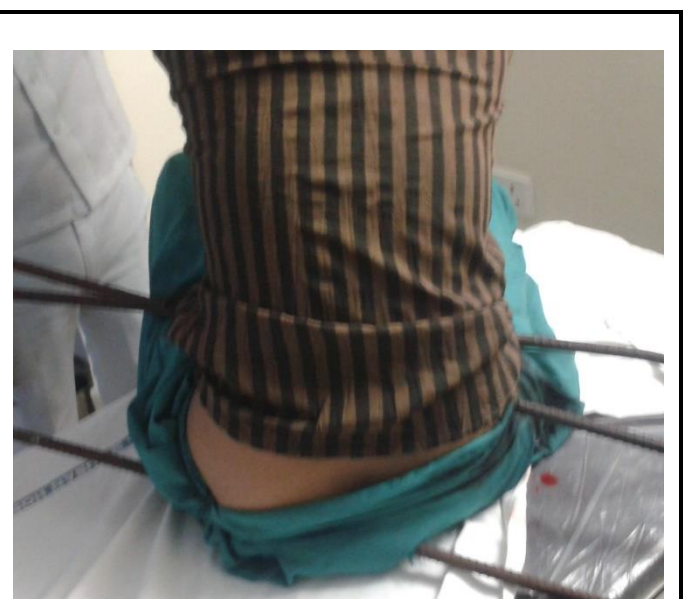


Figure 1: Abdomino-pelvic impalement injury caused by 3 metallic iron rods.

A part of her cloth also went inside the path of the iron rods. Blood clots could be seen at the entry and exit wounds. Abdomen was not distended, and child had passed clear urine once on her way to the emergency department. There was no evidence of any injury to the chest, head, neck, spine or the extremities. At arrival, along with the primary survey, an intravenous line was secured to start fluids, antibiotics and analgesics. Tetanus toxoid and tetanus immunoglobulin were administered. Simultaneously, samples were sent for routine blood investigations and cross match. Haemoglobin was 8.9 and haematocrit was 27. Chest, abdominal and pelvic skiagrams were taken to assess the passage of the rods and any bony injury. One of the rods could be seen penetrating through the right iliac bone.

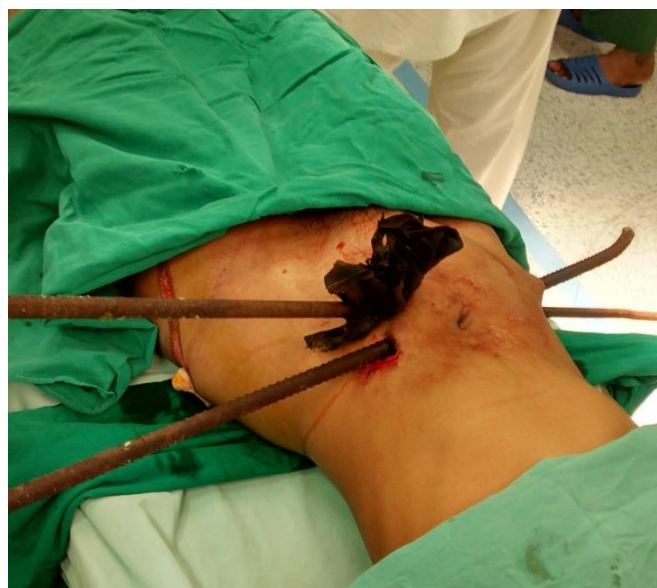

Figure 2: Patient in supine position after removing the first rod (showing 2 other rods penetrating the abdomen).

Patient was shifted to the operation theatre and was put in left lateral position between the operation table and shifting trolley, so that the rods came in between the trolley and the operation table. In this position, patient had induction of anaesthesia using 100% oxygen for 3 minutes followed by Etomidate (100 mg), Fentanyl (75 mcg) and Succinylcholine (75 mg) [Rapid sequence induction], followed by intubation using cuffed orotracheal tube of size 7.0. Following this, patient was maintained on Oxygen, Air and Sevoflurane, then patient was shifted to Operation table in sitting posture and surgical procedure was started. Rod in the gluteal region was removed first after increasing its entry and exit wounds slightly. It was seen to pierce only the

gluteal muscles. The passage was washed with hydrogen peroxide and saline and packed with betadine-soaked gauze. She was then turned supine and laparotomy was done through midline incision. One of the rods was seen to pierce the jejunum twice at approximately 30 and 40 cm from the duodeno-jejunal junction (Figure 3).

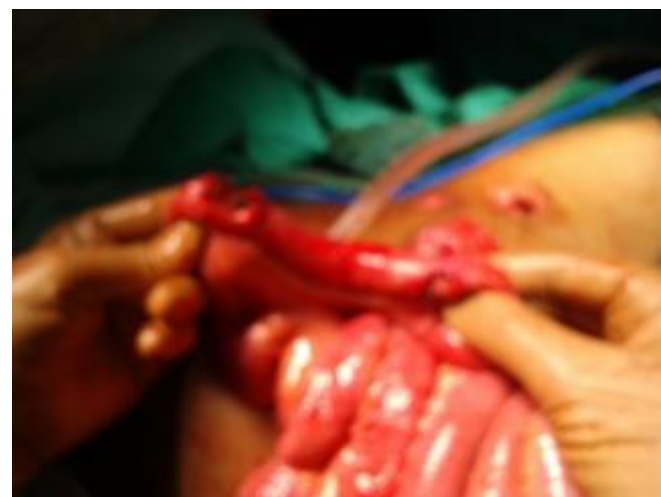

Figure 3: Proximal jejunal segment showing 2 perforations.

Another rod went through and through the ascending colon just distal to the ileo-caecal junction and also the right iliac bone (Figure 4). There were no major vascular or urinary injuries. All the solid organs were spared. Resection of the jejunal segment containing the two perforations was done followed by end-to-end jejunostomy.

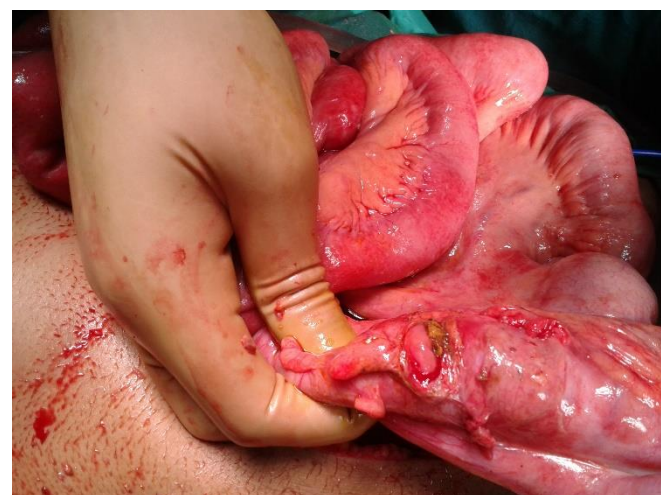


Figure 4: Perforation in ascending colon.

Ileo-ascending anastomosis was done after excision of the caecum along with the perforated ascending colon. No orthopaedic intervention was needed for the rod penetrating the right iliac bone. Tension suturing was done after insertion of drains in pelvis, right and left paracolic gutter. She received three units of packed cells in the peri-operative period. Patient was transferred to the Intensive Care Unit post-operatively and was there for 5 days following surgery for intensive monitoring and management. Antifungal agents were added when positive fungal blood culture was seen following fever on 3rd post-operative day.

Patient passed flatus on 5th post-operative day and tolerated oral food from the next day. Drains were removed on the 5th post-operative day. Wounds over gluteal and iliac regions were conservatively managed on dressing and antibiotics. The total duration of hospitalization was 24 days and patient were discharged with advice of daily dressing of these wounds. First follow-up was after 15 days of discharge and subsequent two follow-ups were after one and three months of discharge. She has been asymptomatic on follow-ups. Figure 5 shows her scars after 3 months of discharge from hospital.

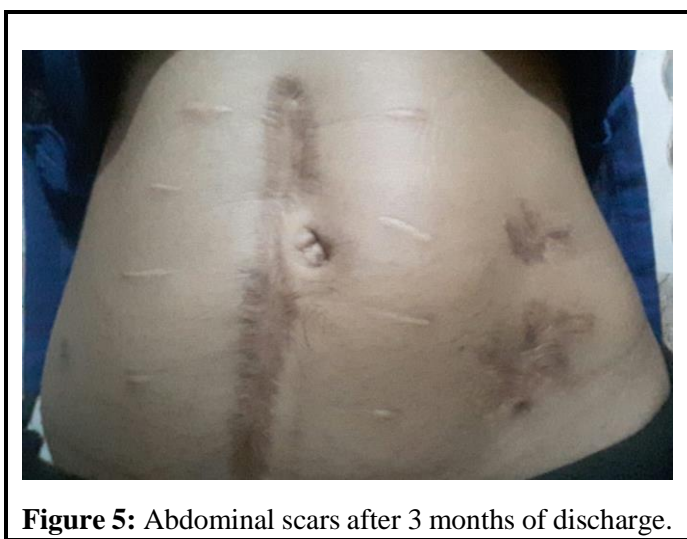

Figure 5: Abdominal scars after 3 months of discharge.

Discussion

Impalement injuries occur when large forces generated by patient's own body weight result in puncture wounds in his body as he falls over an object which is usually fixed [1]. This form of injury is relatively rare and the commonly encountered mechanisms include fall from height, road traffic accidents and stab wounds when the weapon has been left in-situ [1]. Firearm, missile and gunshot wounds have not been included in the spectrum of such injuries.

Morbidity and mortality depends on the organs involved and also the extents of their injuries. Airway or cardiovascular injuries are immediately life-threatening and merit urgent intervention [2]. However, if the patient luckily does not have such injuries, as was the case in our patient, then these patients offer some time for proper transportation to a tertiary care centre for definitive management. The impaled object in such cases should never be removed or disturbed at the accident site or during transportation because it may cause additional injuries which may worsen the patient's condition [3-5].

Also, the impaling object often prevents excessive loss of blood or contamination from faecal matter (as in our case) because it fits snugly to the injured organ. Moreover, removing it in controlled conditions in a hospital helps to identify the exact passage of the impaling object and organs it has penetrated through [2, 3]. In this way, chances of missing a significant injury lessen. Also, we are better equipped to control bleeding or further damages in a hospital setup.

Positioning for anaesthesia can be difficult and sometimes it may not be possible to conduct the anaesthetic procedure in supine position [6]. Haemorrhagic shock may additionally add to the patient's vulnerability.

In our patient, her relatives meticulously cut the iron rods without moving the portion which had penetrated her and this facilitated safe and prompt transport. This also prevented any further injuries or excessive bleeding. Impaling objects are potentially infective, and it is, therefore, important to administer antibiotics and tetanus toxoid. Iron rods in-situ at the site of bowel perforation limited faecal and biliary contamination of the peritoneal cavity. They also helped in identifying all injured organs and in deciding the approach towards surgical management. Patient was lucky not to have any major vessel or solid organ injury.

Conclusion

We concluded that in all stable patients with impalement injuries, safe transport to the operating room, emergent imaging to know the nature and extent of injuries, extraction of impaled objects in the operating room and multidisciplinary care help in better management and improve outcome. Unstable patients should, however, receive prompt intervention.

Conflict of Interest

None declared.

Funding

None declared.

References

1. Edwin F, Tettey M, Sereboe L, et al. Impalement injuries of the Chest. *Ghana Med J* 2009; 43: 86-89.
 2. Rawat JD, Goel P, Kunnur VS, et al. Penetrating injury of pelvis, abdomen and thorax in a child with a trident (Trishula). *APSP J Case Rep* 2013; 4: 3.
 3. Foot CL, Naidoo P. Breaking the rules: A thoracic impalement injury. *Med J Aust* 1999; 171: 676-677.
 4. Vaslef SN, Dragelin JB, Takia MW, et al. Multiple impalement with survival. *Am J Emerg Med* 1997; 15: 70-71.
 5. Horowitz MD, Dove DB, Eismont FJ, et al. Impalement injuries. *J Trauma* 1985; 25: 914-916.
 6. Tantry TP, Kadam D, Shetty P, et al. Penetrating abdominal injury in a polytrauma patient: Anaesthetic challenges faced. *J Anaesthesiol Clin Pharmacol* 2011; 27: 272-274.
-

This manuscript was peer-reviewed

Mode of Review: Single-blinded

Academic Editor: Dr. Ruqaiyah Khan

