Med Case Rep J (2023) Vol 6 (1)

Medical Case Reports Journal

journal homepage: https://mcrj.edwiserinternational.com

Case Report

Rare Adenosquamous Lung Cancer Inducing Large Hemorrhagic Pericardial Effusion in An Undiagnosed Patient

Nilson Tapia[1], Nwakile Ojike[1], Amr Salem[3], Magdalena Rantinella[1,2], Chen Shuang[1] and Ronny Cohen[1,2,]*

[1]NYC Health + Hospitals/Woodhull, Brooklyn, NY, USA
[2]NYU Grossman School of Medicine, New York, NY, USA
[3]Boston University School of Medicine, Boston, MA, USA

ARTICLE INFO

Received 17 January 2023
Revised 03 February 2023
Available Online 06 Feb 2023

*Corresponding author:
Dr. Ronny Cohen; NYC Health + Hospitals/ Woodhull, Brooklyn, NY, USA.

ABSTRACT

While lung cancer is the leading cause of cancer mortality, only 2% of non-small cell lung cancer (NSCLC) cases are classified as the adenosquamous subtype. Here we present a case of a middle-aged man who presented with atypical symptoms of massive malignant hemorrhagic pericardial effusion without cardiac tamponade, induced by adenosquamous non-small cell lung carcinoma. Malignant hemorrhagic pericardial effusions are rare, and large volume ones are even rarer. The patient's advanced malignancy was undiagnosed at presentation and was only discovered through investigations carried out for his pericardial disease. Malignant pericardial effusion may be the initial symptom of malignancy in some patients. Furthermore, adenosquamous carcinoma is a rare type of NSCLC whose response to chemotherapy is limited. Further studies of this rare subtype are warranted to improve patient prognosis.

***Keywords**: Lung cancer, pericardial effusion. Cardiac tamponade, adenosquamous carcinoma*

Introduction

Lung cancer is the leading cause of pericardial effusion[1], it is also the leading cause of mortality in both genders[2]. Eighty five percent of all lung cancer cases in the United States are non-small cell lung cancer (NSCLC)[3], only a small fraction of which are the adenosquamous histological subtype[4]. A buildup of malignant fluid in the pericardial cavity increases pericardial pressure, which when higher than the ventricular pressure reduces ventricular filling and cardiac output. In patients with cancer, pericardial effusions can arise due to primary or metastatic disease, toxicity from chemotherapy or radiotherapy as well as due to immunocompromised status. Patients with pericardial effusions may be asymptomatic but often present with shortness of breath, chest pain or chest discomfort[5]. Other clinical features include palpitations (tachycardia and atrial fibrillation), hypotension, distant heart sounds and pulsus paradoxus. Here we report the case of a middle-aged patient who presented with atypical symptoms of massive malignant, hemorrhagic pericardial effusion without cardiac tamponade, induced by a rare adenosquamous NSCLC.

Case History

In July 2020, a 65-year-old man presented to the emergency department with a one-week history of persistent coughing spells and intermittent epigastric pain that worsened with food intake. There was no history of fever, orthopnea, recent travel or sick contacts. His metabolic exercise tolerance was over four. On physical exam he was hypertensive

(167/67mmhg) with a heart rate of 98bpm, afebrile and non-tachypneic. No jugular venous distention or peripheral edema was noted. Blood work was only remarkable for a while blood count of 11.15 (reference rage 3.90-10.60 x $10^{3/}$ mcL). Electrocardiogram (Figure 1) showed atrial fibrillation with no rapid ventricular rate and no abnormal ST-T wave changes. Atrial fibrillation was likely new onset.

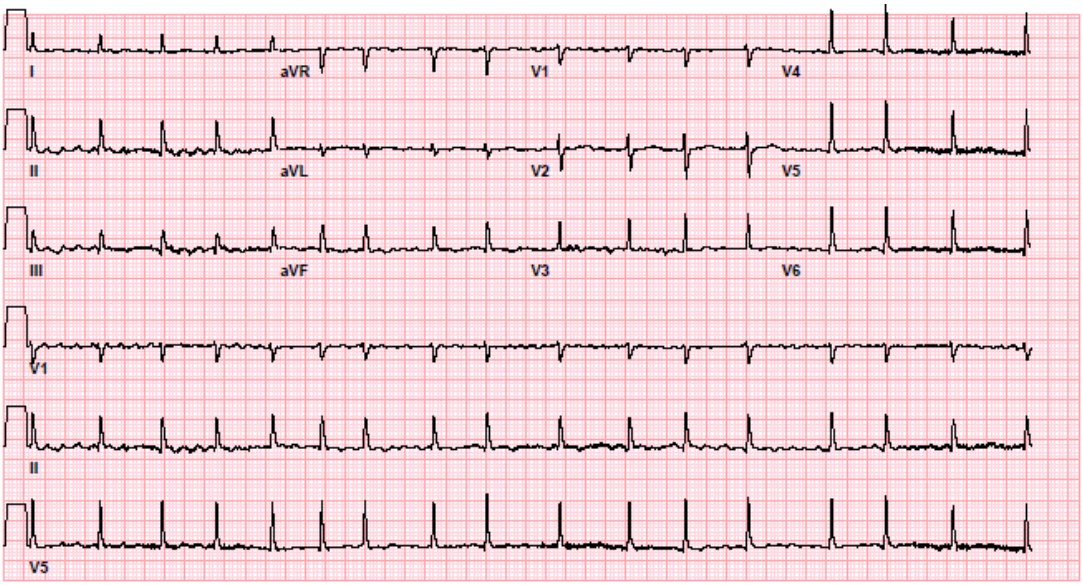

Figure 1: EKG showing new onset atrial fibrillation.

A chest x ray (Figure 2) demonstrated focal increased opacity in the right upper lobe suggestive of acute airspace disease and mild pulmonary vascular congestion. COVID-19 PCD was negative. CT scan of the chest was performed after the pericardial window

.

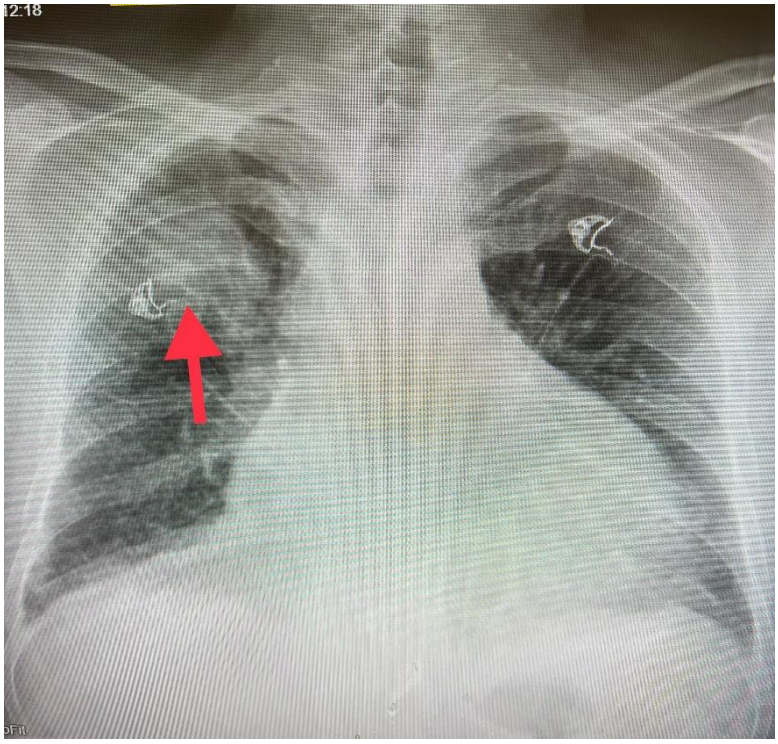

Figure 2: Chest X Ray demonstrating focal increased opacity in the right upper lobe.

A transthoracic echocardiogram (Figure 3) was performed that revealed a large pericardial effusion without tamponade. Fibrin strands were noted in the pericardium. The left ventricular ejection fraction was ~ 65%. The right atrial pressure was elevated to ~ 15mmhg and mild to moderate mitral regurgitation was noted. The patient was seen by vascular surgeon who performed pericardiocentesis 24 hours later. The pericardiocentesis yielded 1.5 Liter od hemorrhagic pericardial fluid. The patient went on to receive a pericardial window via the subxiphoid approach for continuous drainage.

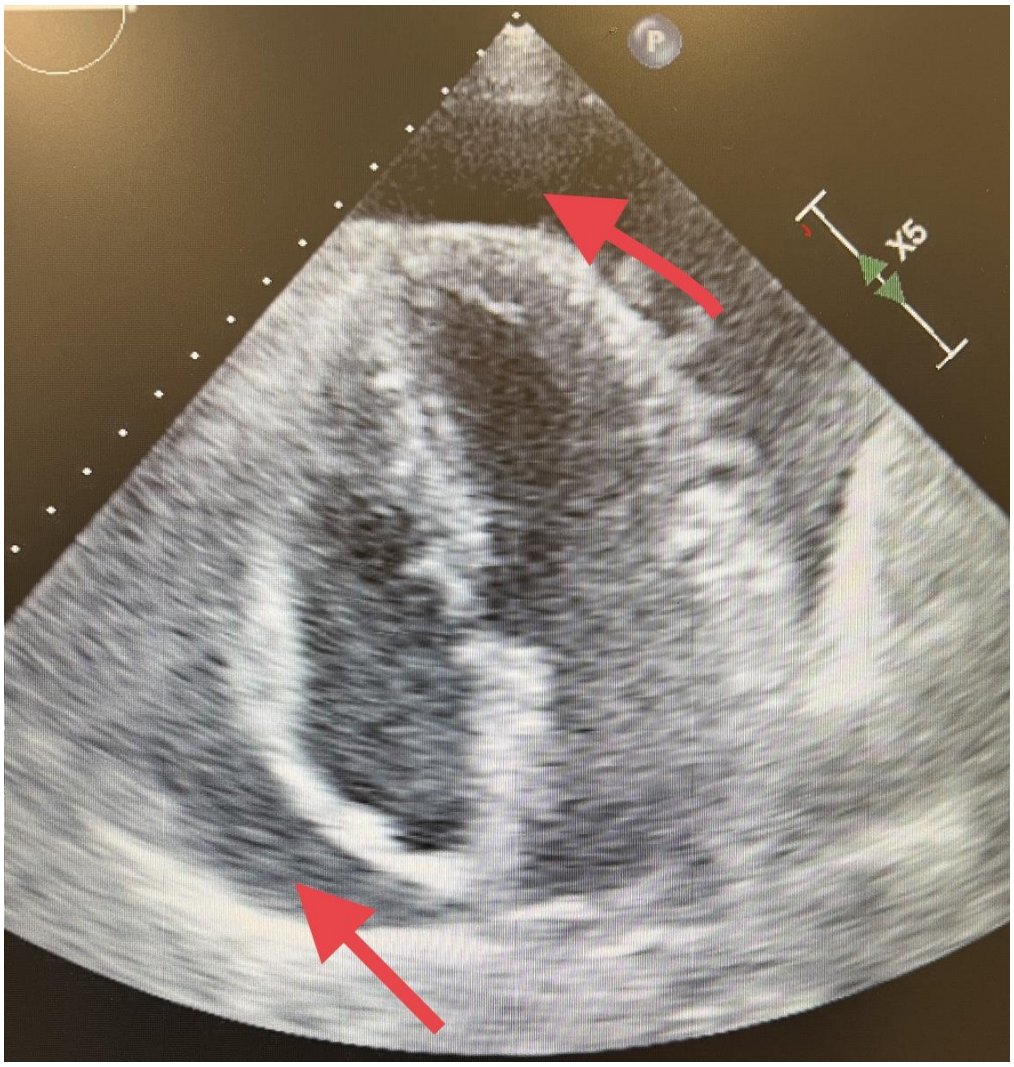

Figure 3: A 3.4 cm circumferential pericardial effusion seen in the four-chamber view.

The patient's acute symptoms resolved, and he remained comfortable without respiratory distress. The pericardial fluid was negative for acid fast bacilli, fungal infection, and both aerobic and anaerobic bacteria. However, fluid cytology yielded dimorphic malignant cells consistent with both a squamous cell and morphology in near-equal distribution. CT scan of the chest (Figure D) showed a large speculated right upper lobe mass with irregular borders, with several prominent mediastinal and left suprahilar lymph nodes, highly suspicious for malignancy as well as large bilateral pleural effusions. Consequently, fine needle aspiration of the right upper lobe mass was performed and cytological examination revealed malignant squamous and glandular cells. The patient was referred to oncology and he was diagnosed with stage IV adenosquamous lung cancer, a rare subtype of NSCLC. Patient care was coordinated between the oncology and palliative teams for further evaluation of treatment options and goals of care, respectively

.

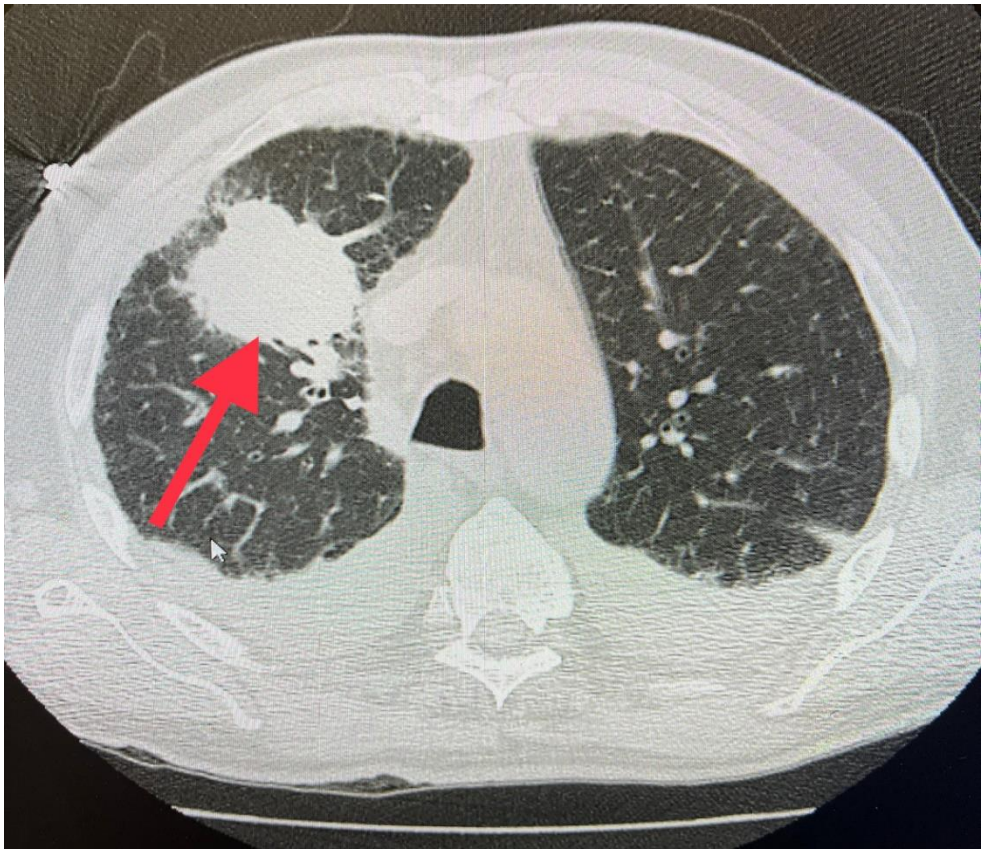

Figure 4: CT scan of the chest showing a large 49mmx47mmx43mm spiculated right upper lobe mass with irregular borders and bilateral pleural effusions.

Discussion

Lung cancer was the most common cancer diagnosed in men in 2018[6]. Adenocarcinoma is the most common subtype of NSCLC with squamous carcinoma accounting for ~ 30% of NSCLC cases[7]. By contrast, only 2% of NSCLC cases are of the adenosqumous subtype. The adenosquamous carcinoma of the lung is comprised of both squamous and glandular cells. The prognosis is very poor compared to adenocarcinoma or squamous cell carcinoma of the lung individually[8].

Hemorrhagic pericardial effusions are commonly associated with malignancy. Other causes include tuberculosis, percutaneous interventional procedures, myocardial infarctions, trauma, uremia, or idiopathic (least common cause)[9]. In cancer autopsy studies, it was observed that approximately 1 in 25 cases with cardiac metastases had primary lung cancer, making it the most common primary tumor site of the cases. Adenocarcinoma was the most common lung carcinoma cell type found. Furthermore, only 11% of total cases with cardiac involvement were associated with hemorrhagic pericardial effusions[10].

We present a case of a middle-aged man who presented with atypical symptoms of massive malignant hemorrhagic pericardial effusion without cardiac tamponade, induced by NSCLC of adenosquamous rare subtype. The patient's malignancy was initially undiagnosed, and only discovered through pericardial workup, only to find his malignancy at an advanced stage.

This case sheds light onto a rare type of NSCLC whose studies on response to chemotherapy is limited and warrants further investigation to improve patient prognosis.

Acknowledgement

None to declare.

Financial Disclosure

No funding to declare.

Conflict of Interest

None to declare.

Informed Consent

Not applicable.

Author Contributions

All authors contributed equally to the case report.

Data Availability

The authors declare that data supporting the findings of this study are available within the article.

References

1. El Haddad D, Iliescu C, Yusuf SW, et al. Outcomes of Cancer Patients Undergoing Percutaneous Pericardiocentesis for Pericardial Effusion. J Am Coll Cardiol 2015 Sep 8;66(10):1119-28.
2. U.S. Cancer Statistics Working Group. U.S. Cancer Statistics Data Visualizations Tool, based on 2019 submission data (1999-2017): U.S. Department of Health and Human Services, Centers for Disease Control and Prevention and National Cancer Institute; www.cdc.gov/cancer/dataviz released in June 2020. Accessed February 16, 2021.
3. Molina JR, Yang P, Cassivi SD, et al. Non-Small Cell Lung Cancer: Epidemiology, Risk Factors, Treatment, and Survivorship. Mayo Clin. Proc 83 (5) (2008), pp. 584-594.
4. Travis WD, Brambilla E, Burke AP, et al. WHO Classification of Tumours of the Lung, Pleura, Thymus and Heart. Lyon: International Agency for Research on Cancer; 2015.
5. Stolz L, Valenzuela J, Situ-LaCasse E, et al. Clinical and historical features of emergency department patients with pericardial effusions. World J Emerg Med 2017; 8(1): 29-33.
6. Global cancer statistics 2018: GLOBOCAN estimates of ... (n.d.). Retrieved July 12, 2020, from https://acsjournals.onlinelibrary.wiley.com/doi/full/10.3322/caac.21492
7. Types of Lungs Cancer: Common, Rare and More Varieties. (2020, June 19). https://www.cancercenter.com/cancer-types/lung-cancer/types.
8. Naobumi Tochigi, Sanja Dacic, Marina Nikiforova, et al. Adenosquamous Carcinoma of the Lung: A Microdissection Study of KRAS and EGFR Mutational and Amplification Status in a Western Patient Population, American Journal of Clinical Pathology, Volume 135, Issue 5, May 2011, Pages 783–789.
9. Atar S, Chiu J, Forrester JS, et al. Bloody pericardial effusion in patients with cardiac tamponade: is the cause cancerous, tuberculous, or iatrogenic in the 1990s?. *Chest*. 1999;116(6):1564-1569.
10. Klatt EC, Heitz DR (1990). Cardiac metastases. *Cancer*, *65*(6), 1456–1459.