



## *The Breastfeeding Dilemma: Misdiagnosed TOTS or Just Ignoring their Existence?*

Lawrence A Kotlow\*

Pediatric Dentist, 340 Fuller Road, Albany, New York 12203, USA

### Article info

Received 20 February 2018

Revised 12 March 2018

Published 19 March 2018

\*Corresponding author: Lawrence A Kotlow, Pediatric Dentist, 340 Fuller Road, Albany, New York 12203, USA; E-mail: [kiddsteeth@aol.com](mailto:kiddsteeth@aol.com)

### Abstract

Parents have great expectations for motherhood. Unfortunately for many mothers, breastfeeding becomes a toe-curling, painful experience because of poor or missed diagnosis of tethered oral tissues also known as TOTS. The majority TOTS are primarily a combination of tongue-ties, medically known as ankyloglossia, and upper lip-ties. There are many unfortunate barriers for mothers getting good sound advice and a diagnosis of tongue-ties and lip-ties as the cause of their maternal and infant breastfeeding difficulties. Scientific plausibility can and often should be substituted for the concept of evidence-based knowledge when we look at the accumulated experience, education, and clinical skills of many practitioners who have been revising infants TOTS for years with great success. Revision these tethered tissues is not just for breastfeeding, but the tethered tongue can also affect many other body functions and systems.

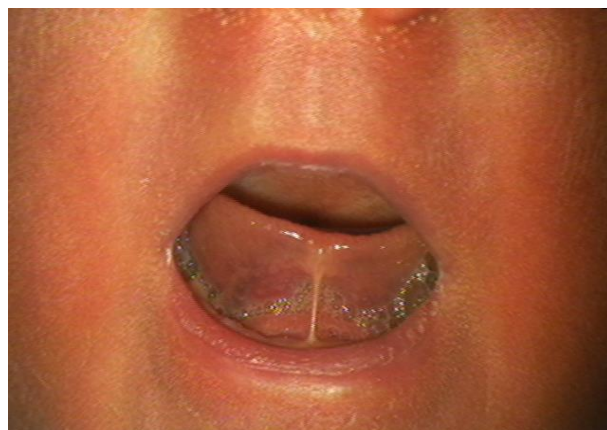
**Keywords:** Breastfeeding; Anesthesia; Aerophagia; Sleep apnea; Cognitive impairment.

### Opinion Article

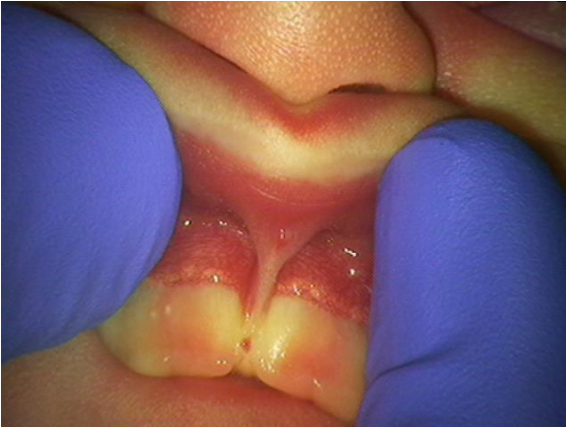Parents have great expectations for motherhood. Unfortunately for many mothers, breastfeeding becomes a toe-curling, painful experience because of poor or missed diagnosis of tethered oral tissues. These TOTS are usually a combination of tongue-ties, medically known as ankyloglossia and upper lip-ties. They benefit breastfeeding by the release of the maxillary lip-tie and in some instances upper buccal restrictive frenum attachments which prevent the infant from achieving a good latch onto the mother's areola [1-3].

For nine long months parents eagerly anticipated the birth of their child. The day finally arrives and immediately after the baby is born, the newborn infant is placed on a mother's chest and the mother-infant bond is supposed to begin, but something seems wrong. As the infant attempts to latch onto the mother's breast, it hurts, something is not right (Figures 1-3).

While still in the hospital, the family ask to see a lactation consultant and speak to her to doctor.



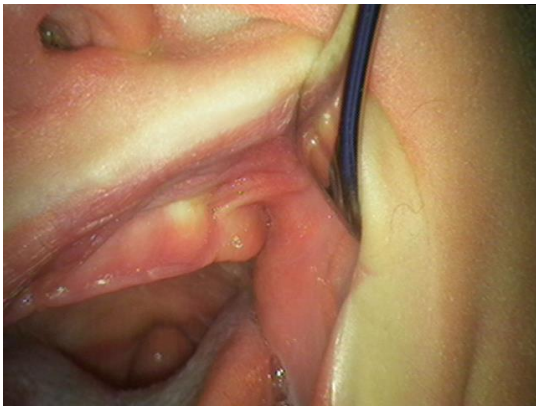**Figure 1:** Class IV lingual tie.



**Figure 2:** Class 3 maxillary lip-tie.

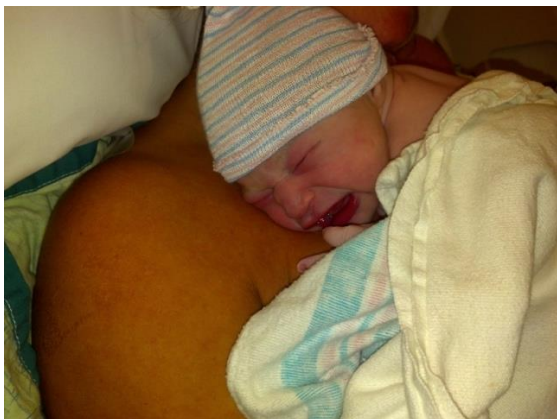

**Figure 5:** Mother and infant dyad having painful breastfeeding experience.



**Figure 3:** Maxillary buccal tie.

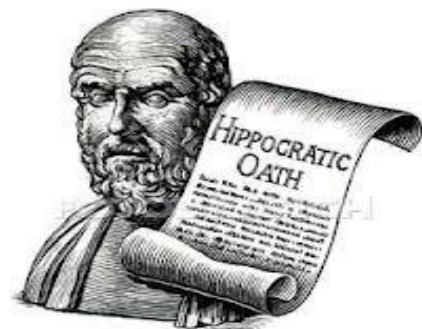As a mother, parents know something is wrong, but all the available support systems are dismissing parental concerns as those of a new mother.



**Figure 4:** Newborn infant resting on mother's chest immediately after birth.

There are many unfortunate barriers for mothers getting good sound advice and a diagnosis of tongue-ties and lip-ties as the cause of their maternal and infant breastfeeding difficulties [4] (Figures 4,5).

#### **Do No Harm**



**Figure 6:** Hippocratic oath.

The first problem and one of the most difficult, is changing old medical concepts believing that doing no treatment is better than doing any surgical treatment. Often the medical Hippocratic Oath of “doing no harm”, is misrepresented as just watching and waiting (Figure 6). The concept of medically necessary care is the first hurdle we need to jump over.

As defined by the American Academy of Pediatric Dentistry in their guidelines, medically necessary care (MNC) is the reasonable and appropriate diagnostic, preventive treatment services and follow-up care as determined by qualified, appropriate health-care providers in treating any condition, including a disease, an injury, or a congenital or developmental malformation [5]. In addition, it states that medically

necessary care includes all supportive health-care services that, in the judgment of the attending dentist, are necessary for the provision of optimal quality therapeutic and preventive oral care.

Thus, we can reasonably say that revising the lip and tongue-ties in infants with symptoms of breastfeeding difficulties meets the requirement of a congenital or developmental malformation requiring a therapeutic and preventive intervention for optimal oral care.

The second significant barrier to treatment is the medical community's reluctance to understand the idea of evidence-based knowledge and how it can be assimilated into the concept of scientific plausibility. Scientific plausibility can and often should be substituted for the concept of evidence-based knowledge when we look at the accumulated experience, education, and clinical skills of many practitioners who have been revising infants TOTs for years with great success.

Modern medicine has not been able to decide where breastfeeding problems should be addressed. Since breasts are partially where the problems are observed, is it the OB/GYN physician who should be treating the problem? Or since it is the infant who presents with the problems and indeed is the real source of the problem, does the pediatrician or family practice physician assume the responsibility? All too often neither is equipped to do so. The result is that mothers continue to suffer and nothing really changes.

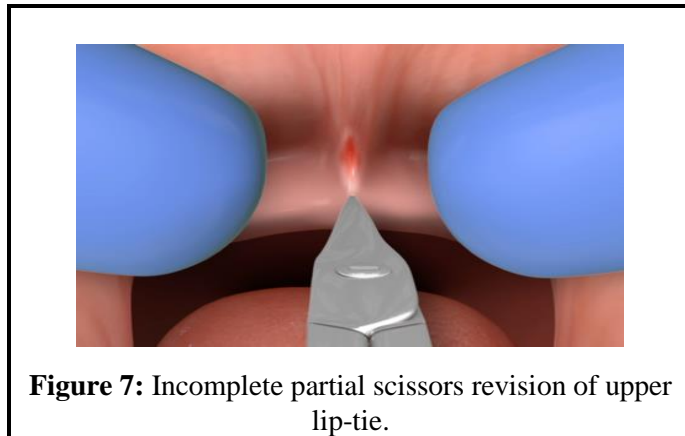
### The Breastfeeding Team

In an ideal world, we should have a "breastfeeding team". The breastfeeding team would consist of the delivery room nurse or midwife for home births, followed by the pediatrician or family practice physician, the IBCLC, often a body worker such as an infant chiropractor or cranial-sacral therapist and the pediatric or family practice dentist. A simple finger sweep across the floor of the mouth can help indicate if breastfeeding is going to be problematical or be a wonderful beginning. This can be performed by a trained nurse in the delivery room, in the nursery or at the mother's bedside.

### The Quick Snip

The first option for treatment if and when TOTs are diagnosed, which I recommend to avoid if at all possible, is the so-called "quick snip". This is when any physician takes a pair of scissors and releases a few millimeters of tissue under the tongue. In almost all instances, this is an incomplete, insufficient, and inadequate release of the tissue (Figure 7). In addition,

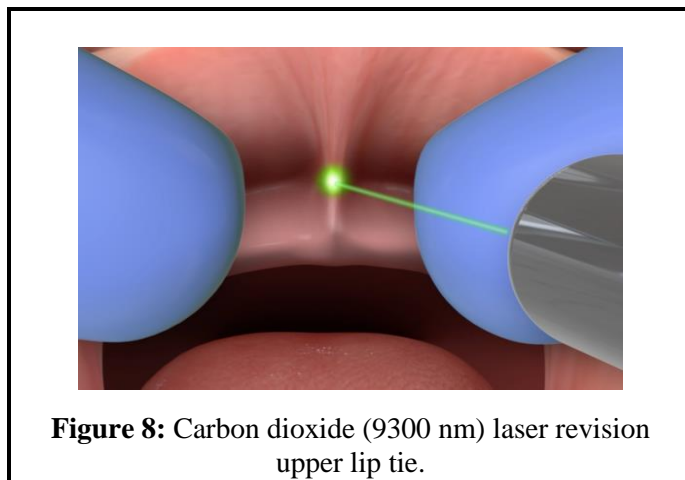
this person will rarely examine, evaluate, or even recognize the need to revise or release the upper lip-tie. Resolution of the symptoms is delayed and mothers still need to see someone for further treatment.



**Figure 7:** Incomplete partial scissors revision of upper lip-tie.

### Medical Referral

The next option is often a referral from the primary care physician to an ear, nose, and throat specialist (ENT) physician. Usually the same procedure occurs: a quick snip with a pair of scissors and an assurance to you that the upper lip has no effect on achieving a good latch. If the ENT agrees that these tissues need to be released or revised, he or she often suggests waiting until the infant is older and/or then doing the procedure in an operating room under a general anesthetic. This option doesn't address the immediate problems and will often lead to premature weaning to the bottle, but with the infant's symptoms remaining. Placing an infant under general anesthesia at this age is neither recommended nor necessary when other options are far safer and less invasive.

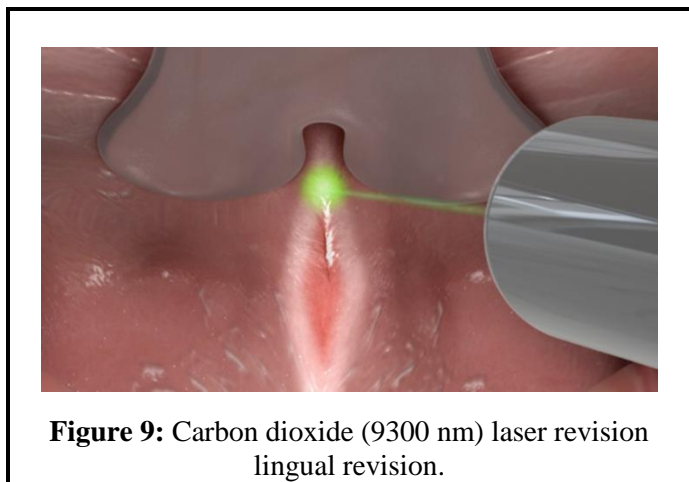


**Figure 8:** Carbon dioxide (9300 nm) laser revision upper lip tie.

### The Laser Option

I recommend seeking someone trained and educated in the use of surgical soft-tissue dental lasers [6]. Laser

revisions are quick, safe, and easily completed in a few minutes in a dental office or the office of a physician who is trained in laser surgery (Figures 8,9).



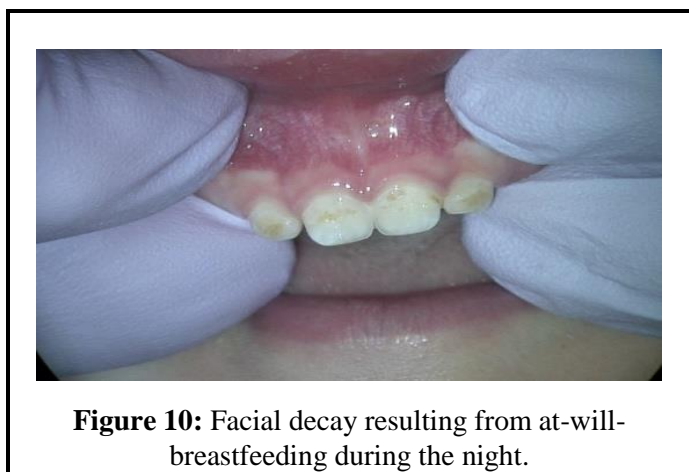
**Figure 9:** Carbon dioxide (9300 nm) laser revision lingual revision.

### It's not Just Breastfeeding Affected By TOTS

#### 1. Air induced reflux:

While it may be true that symptoms of (GER) will eventually resolve as the infant gets older, advising parents to just wait it out and have their infants continue to have pain, cry, act fussy, and remain uncomfortable from three to twelve months is not comforting for parents [7,8].

When an infant is found to be swallowing large amounts of air into the stomach, a condition known as aerophagia or air-induced reflux, can force the stomach's content upward, which is then followed by regurgitation or even projectile vomiting of the contents



**Figure 10:** Facial decay resulting from at-will-breastfeeding during the night.

#### 2. Dental decay:

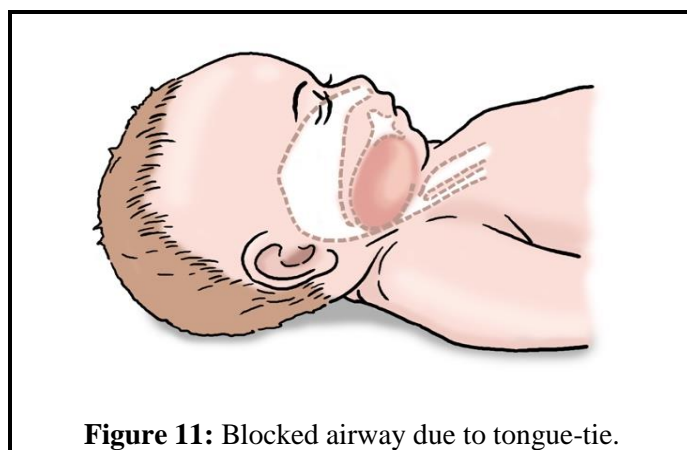
On the upper front teeth as teeth erupt [9] differential diagnostic with nursing mothers indicated that these infants were receiving nutrition entirely from breast milk and that these infants were sleeping with the mother

and engaging in at-will night time breastfeeding among with significant upper lip-tie (Figure 10).

#### 3. Infant sleep apnea:

It can be a significant concern and may be caused when an infant's tongue is tethered and the tongue's resting position ends up in the infant's airway. This is often why an infant begins to gag whenever you place something such as a breast, a pacifier or a bottle into the infant's mouth. In effect the tongue is blocking the infant's airway (Figure 11).

Obstructive sleep apnea (OSA) in infants should be a significant concern for both the parents and health-care professionals [10]. The results of OSA may express themselves as cognitive impairment, attention and hyperactivity disorders, poor academic achievement, disruptive behaviour in school and cardiovascular and metabolic complications.



**Figure 11:** Blocked airway due to tongue-tie.

#### 4. Mother's symptoms attributed to TOTS:

- Thrush
- Mastitis
- Blocked ducts
- Postpartum depression
- Bleeding, painful and cracked nipples
- Reduced milk reduction [11].

Infants and mothers experiencing difficulties with breastfeeding, primarily due to an ineffective or poor latch, experience many symptoms. Breastfeeding is usually expressed as involving two individuals, the mother and the infant (dyad), and if either one of these individuals suffer symptoms related to an infant's latch, however when these two are affected, the father also becomes part of the equation, so in effect it is a breastfeeding triad. Revising TOTS will usually improve the breastfeeding experience and reduce or eliminate most symptoms.

### Conflict of Interest

None declared.

### Funding

None declared.

### References

1. Fitz-Desorgher R. All tied up: Tongue tie and its implications for breastfeeding. *Pract Midwife* 2003; 6: 20-22.
2. Garbin CP, Sakalidis VS, Chadwick LM, et al. Evidence of improved milk intake after frenotomy: A case report. *Pediatrics* 2013; 132: e1413-1417.
3. Kotlow L. SOS 4 TOTs. The Troy Bookmakers, Troy, NY, 2016.
4. Brignardello-Petersen R, Carrasco-Labra A, Glick M, et al. A practical approach to evidence-based dentistry: Understanding and applying the principles of EBD. *J Am Dent Assoc* 2014; 145: 1105-1107.
5. American Academy of Pediatric Dentistry Guidelines 2017.
6. Kotlow L. Diagnosis and treatment of ankyloglossia and tied maxillary fraenum in infants using Er:YAG and 1064 diode lasers. *Eur Arch Paediatr Dent* 2011; 12: 106-112.
7. Kotlow L. Infant reflux and aerophagia associated with the maxillary lip-tie and ankyloglossia (tongue-tie). *Clin Lact* 2011; 2: 4.
8. Siegel S. Aerophagia induced reflux in breastfeeding infants with ankyloglossia and shortened maxillary labial frenula (tongue and lip tie). *Int J Clin Pediatr North Am* 2016.
9. Kotlow LA. The influence of the maxillary frenum on the development and pattern of dental caries on anterior teeth in breastfeeding infants: Prevention, diagnosis, and treatment. *J Hum Lact* 2010; 26: 304-308
10. Gozal D. Obstructive sleep apnea in children: Implications for the developing central nervous system seminars in pediatric neurology. 2008; 15: 100-106.
11. Dollberg S, Botzer E, Grunis E, et al. Immediate nipple pain relief after frenotomy in breast-fed infants with ankyloglossia: A randomized, prospective study. *J Pediatr Surg* 2006; 41: 1598-1600.

---

*This manuscript was peer-reviewed*

*Mode of Review: Single-blinded*

*Academic Editor: Dr. Ibrahim Anwar Ahmed Abdelazim*

