Medical Case Reports Journal

Available Online: http://mcrj.edwiserinternational.com

Immunotherapy in Anaphylaxis by Tropical Fire Ant Sting: A Case Report and Literature Review

Collado Chagoya Rodrigo, Hernández Romero Javier, Eliosa Alvarado Gumaro Alejandro, Garcia Gonzalez Ana del Carmen, Campos Gutierrez Rosa Isela, Velasco Medina Andrea and Velázquez Sámano Guillermo*

Department of Clinical Immunology and Allergy, Hospital General de México, (Dr. Eduardo Liceaga), Mexico

Article info

Received 25 February 2018
Revised 20 April 2018
Published 26 April 2018

*Corresponding author: Rodrigo CC, Department of Clinical Immunology and Allergy, Hospital General de México, (Dr. Eduardo Liceaga), Mexico; E-mail: rodnova87@hotmail.com

Abstract

The Hymenoptera constitute an insect order in which they are included wasps (superfamily Vespideae), bees (superfamily) Apoideae) and ants (superfamily Formicidae). Hymenoptera stings can become a serious allergic reaction, fast instauration and potentially deadly. The ants are an subestimated source of hypersensitivity reactions in Mexico, being the most associated species Solenopsis Geminata (Tropical Fire Ant), Pogonomyrmex (Harvester ant) and Camponatus (Carpenter Ant). Being Immunotherapy the only effective preventive treatment in future exposures. We present a case of anaphylaxis secondary to the tropical fire ant sting in a field worker from the state of Guerrero, its diagnostic protocol and sustained success by an individualized protocol of Subcutaneous Immunotherapy with Whole Body Extract (WBE). Future research is needed on the ant biodiversity, its allergenic components in the venom and future reports and standardization with the use of immunotherapy being this the first case of immunotherapy in Tropical Fire Ant (Solenopsis Geminata).

Keywords: Anaphylaxis, Bite Sting, Fire Ant, Solenopsis Geminata, Immunotherapy.

Introduction

The ants are hymenoptera that make up the family formicidae, being part of the vespidae superfamily. From the 16 ant subfamilies that exist, only six are distributed in all regions: Cerapachyinae, Dolichoderinae, Formicinae, Myrmicinae, Ponerinae and Pseudomyrmecinae [1]. To know the number of species of ants registered for Mexico to date, were consulted the data for Mexico stored in AntWeb, which is the largest online ant database of the world and local database [2].

Chiapas, Veracruz and Hidalgo are the states with more species, states that have fewer species and genres are Tlaxcala and Aguascalientes. The Myrmicinae and Formicidae families have the highest number of species, following the pattern that has already been pointed out in the world mirmecofauna [3].

It is well known that some aggressive ants, including Solenopsis (Fire Ant), Formica (wood ant), Myrmecia (jack jumper ant), Tetramorium, Pogonomyrmex (Harvester ant), Pachycondyla (Samsum ant), Odontomachus (trap-jaw ant), Rhytidoponera a (greenhead ant), Pseudomyrmex (twig or oak ant), and Hypoponera, have episodically been reported to cause severe reactions. In Mexico most of the cases reported to a severe systemic allergic reaction have been to the Genus Solenopsis, Pogonomyrmex, Camponotus and Pheidole. Of these the most involved species has been Solenopsis Geminata (Figure 1) [3,4].

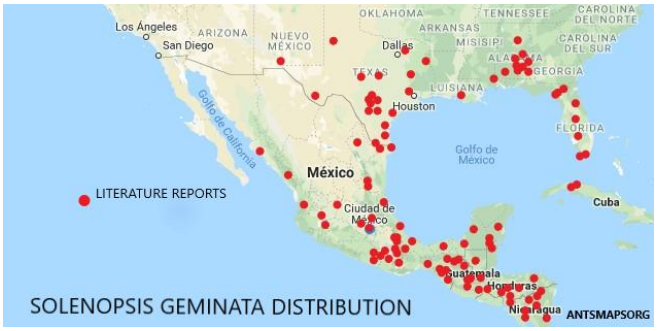

Figure 1: Distribution of literature reports of solenopsis geminata in mexico (data from ant web and antsmapsorg); original Figure 5.

Stings from imported red fire ants (Solenopsis invicta) black fire ants (Solenopsis richteri) and tropical fire ant (Solenopsis Geminata) typically result in a wheal and-flare response accompanied by a burning sensation, followed within 24 hours by sterile pustule formation [5].

This pustule is the result of transpiperidine alkaloids that cause local tissue necrosis; it can last for several days and is considered pathognomonic of fire ants stings (Figure 2) [6].



Figure 2: Solenopsis geminata photography in the state of guerrero, Mexico.

Large local reactions (LLRs) can also occur and can occasionally be debilitating. Systemic reactions (SRs) to Fire Ants stings are well described. Anaphylaxis occur in about 2% and more than 85 fatalities have been documented [6].

It is estimated that each Fire Ant sting delivers about 100 ng of protein compared with 50,000 ng (50 mg) of protein delivered by flying Hymenoptera. Fire Ant venom differs from other Hymenoptera venoms (70% protein content) in that only 2-5% of its content is protein. The majority (90-95%) of Fire Ants venom is composed of piperidine alkaloids. Although most of the proteins contained in its venom are not allergenic. The majority (90-95%) of Fire Ants venom is composed of piperidine alkaloids which is responsible for its characteristic injury (pustule) from the sting. The venom has cytotoxic, insecticidal, antibiotic and antimicrobial properties as well [7].

The protein components of Solenopsis geminata venom, are allergens similars to the Imported Fire Ant (Solenopsis Invicta), and have four principal allergenic proteins Sol gem 1, Sol gem 2, Sol gem 3 and Sol gem 4.

After evaluating Sol gem 2 under non-reducing and reducing conditions, its native form was identified as a dimer with molecular weights of 28 and 15 kDa and allergenic properties similar to Sol i 2 of S. invicta which would explain the great cross-reactivity between these species [8]. The cross reactivity between ant species (Solenopsis Richteri, invicta) has been demonstrated and in the same way between fire ants, scorpions (Centruroides vittatus) and wasp (Yellow wasp) [7,8].

Diagnosis of ant-induced hypersensitivity can be performed by documenting a patient history of allergic reaction to ant stings, by physical examination, or through the use of *in vivo* and/or *in vitro* tests. Diagnosis of ant hypersensitivity is based mainly on a clinical suspicion and the demonstration of sensitization by *in vivo* test (skin tests) or in the case of the correctly standardization of their allergen proteins by *in vitro* test.

The method most commonly used in the case of fire ant hypersensivity are skin testing using imported fire ant WBE using a concentration of 1:1000 (w/v) concentration of tropical fire ant WBE. In the case of a negative result, an intradermal skin test with concentrations of 1:1,000,000 to 1:1000 (w/v) of the tropical fire ant WBE should be performed [8,9].

Serum specific IgE to Imported fire ant venom (Solenopsis Invicta) can be used as an *in vitro* test to diagnose hypersensitivity to imported fire ants but it is not adequately studied and standardized in tropical fire ants (Solenopsis Geminata) and having a lower sensitivity to skin tests should only be done in cases of difficult diagnosis and/or negative skin tests [8,9].

The allergist's role in the patient with fire Ants hypersensitivity is of outmost importance. Management

is divided into acute treatment for anaphylaxis and preventive treatment to avoid recurrent events. Within preventive treatment the most important is the introduction of subcutaneous immunotherapy (SCIT) with IFA whole-body extract (WBE) and avoiding further exposure [10].

Case Reports

Fifty-six years old female from the state of Guerrero, field worker, who attends our service for presenting on two occasions reactions to the sting of an ant. The first occasion refers to the appearance of a lesion described as "pustule" in the external region of the foot and 15 minutes later presenting lesions described as "hives" throughout the body receiving treatment with antihistamines and being classified as acute urticaria.

The second occasion refers to feeling a sting in the arm while working and presenting after 5 minutes the appearance of hives all over the body, followed by wheezing, chest tightness and dyspnea, having to be taken to the emergency room being classified as anaphylaxis and needing treatment with adrenaline, steroids and bronchodilators.

Based on the background, hymenoptera allergy is suspected and studies are initiated to rule out atopy. Finding Immunoglobulin E of 478 UI wth the rest of laboratories within normal parameters including spirometry. The patient is asked to take pictures of the insects present in their workplace, mostly referring to the presence of red ants, we ask that other colleagues collect some specimens for further study.

In both cases they were classified as solenopsis Geminata by the taxonomist. Therefore, it was decided to perform skin tests according to the method recommended by the subcommittee of the American Academy of Allergy, Asthma & Immunology (AAAAI). We perform skin testing with positive (histamine 1-10) and negative controls (saline 1-10) in an alternate pattern on the volar surface of the forearm including bee, wasp, solenopsis invicta (commercial extract Allergomex), solenopsis Geminata (whole body extract) obtaining negative results.

Performing then intracutaneous test reaction with 1: 1000 dilution obtaining positive results with erythema and a measurement of 4 mm above the negative control for Solenopsis Invicta, Solenopsis Geminata and Wasp. (Figure 3).

We diagnosed allergy to Himenopters and taking into account the cross reactivity between Solenopsis Invicta and Solenopsis Geminata, and the absence of reports of Solenopsis Invicta in the state of Guerrero. It was considered that the patient only sensitized to Solenopsis Geminata and considering the successful response to immunotherapy in Solenopsis Invicta and the similarity between their allergenic proteins.

We decide to initiate immunotherapy to Solenopsis Geminata with non-standardized whole-body extract of Solenopsis Geminata mixed with non-standardized whole-body extract of Solenopsis Invicta in the form of subcutaneous administration under a conventional induction scheme (4-6 months to reach maintenance dose) and reaching a standard maintenance dose of 100 mcg without any adverse reaction (Table 1).

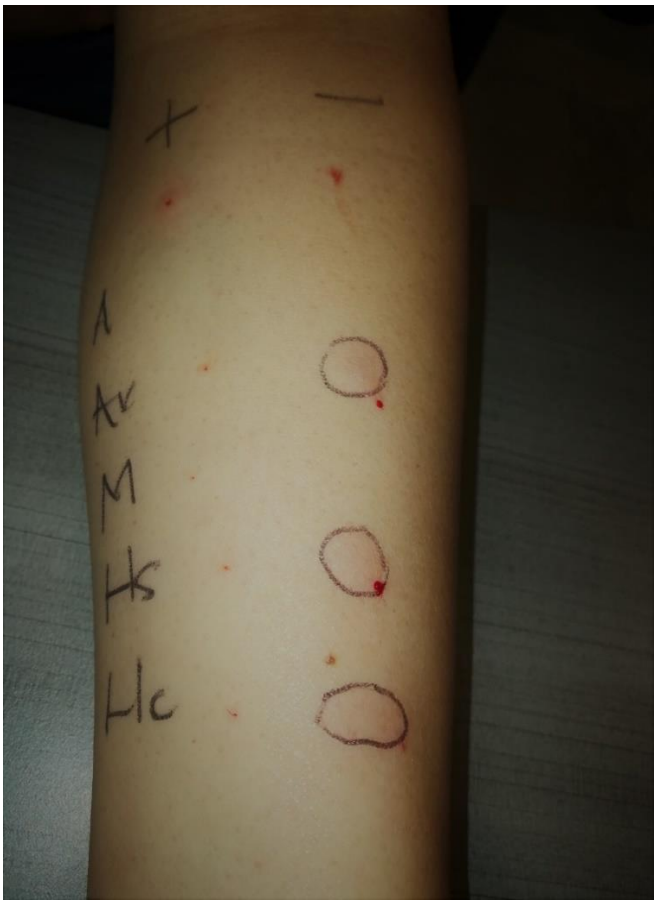

Figure 3: Prick test and intradermal tests; A: Honeybee (Apis mellifera); AV: Common Wasp (Vespula vulgaris), M: Mosquito (Culex pipiens); HS: Imported Fire Ant (Solenopsis Invicta), HC: Tropical Fire Ant (Solenopsis Geminata) +: Histamine -: Control, Test *in-vivo*: Positive by Intradermal Test to Common Wasp, Solenopsis Invicta and Solenopsis Geminata. (Erythema, infiltration, papules).

Follow-up was provided during a 3-year period, for the time being asymptomatic and being able to continue her activities life normally in her social and work environment.

Table 1: Subcutaneous immunotherapy scheme for Solenopsis geminata in the department of Clinical Immunology and Allergy "Hospital general de Mexico".

Schedule of immunotherapy treatment	
Initial	Phase (Biweekly)
0.001 mcg/ml	0.1
	0.2
	0.4
	0.8
0.01 mcg/ml	0.1
	0.2
	0.4
	0.8
0.1 mcg/ml	0.1
	0.2
	0.4
	0.8
1 mcg/ml	0.1
	0.2
	0.4
	0.8
10 mcg/ml	0.1
	0.2
	0.4
	0.8
100 mcg/ml	0.1
	0.2
	0.4
Maintenance	Phase
50 mcg/ml	0.50 cc (Weekly)
Mixed non-standardized whole-body extract of solenopsis geminata with non-standardized whole-body extract of solenopsis invicta.	

Discussion

Phylum Arthropoda constitutes 75% of the animal kingdom, including the orders of the dipterans, constituted by flies and mosquitoes, and the Hymenoptera, conformed by bees, ants, wasps and bumblebees. Hymenoptera order is one of the largest orders of living beings, is made up of about 200,000 species [1,2]. Various chemical components from insects of the orders Hymenoptera and Culicidae have been implicated with allergic reactions. The red ants belong to the Solenopsis genus originating in America. They are small ants that live next to anthills of big species, to which they steal their food. The three most important species, S. richteri, S. invicta and S. Geminata can give rise to true hybrids with the ability to adapt to higher altitudes and tolerate lower temperatures. In Mexico, they are present in a forest remnants but most abundant on a dirt roads and near coffee plantations.

Allergy to the red ants has called of important way the attention in diverse regions of the world. In the United States, we analyzed the results of a sample of patients with asthma, allergic rhinitis or both, 38 adults and 162 children, and found that 5% of them were sensitized to ants. In Mexico in children with allergic diseases, a 6% sensitization to red ants was found [11]. The tropical fire ant (S. geminata) is like the rest of fire ants a highly aggressive species, and its stings can generate severe adverse reactions such as anaphylaxis [12]. The main toxic chemicals are 2-alkyl-6-methylpiperidine alkaloids, δ-lactone and α-pyrone. The majority (90-95%) of IFA venom is composed of piperidine alkaloids which are responsible for the characteristic pustule seen after an IFA sting with his cytotoxic and hemolytic properties. Ant venoms are composed of various biologically active peptides and protein components with each ant species having a variety of major allergenic proteins. Each S. invicta sting transfers 0.04 to 0.11 µL of venom and 10 to 100 ng of proteins (50 ng) [12].

The International Union of Immunological Studies Allergen Nomenclature Subcommittee (IUIS) has assigned official names to tropical fire ant allergens based on venom proteins: 1 was assiganted to Sol gem 1 which has a mass of 32 kDa. Number 2 was assigned to Sol. G 2 which molecular weight is 28 and 15 kDa and presumably has allergenic properties similar to those of Sol i 2 and and it's supposed to be the major allergen of Solenopsis Geminata, and the protein identification is similar to three other fire ant allergens, Sol g 4, Sol r 2 and Sol i 4; Number 3 was assiganted to Sol. g. 3 who has a mass of 24 kDa, number 4 was assignated to Sol. G. 4 which has a mass of 14 kDa and don't have cross reactivity with Sol. G. 2 [13].

Cross-reactivity among insects and ants have been established for some hymenoptera venoms with studies reporting cross-reactivity among major proteins of

vespids (yellow jackets), scorpions and S. invicta. Studies have demonstrated antigenic cross-reactivity for different ant species within the genera Solenopsis (Solenopsis Richteri, Solenopsis Invicta) and Pogonomyrmex [13]. In this case we could suggest the presence of cross-reactivity between solenopsis invicta and solenopsis geminate, as well as the cross-reactivity between solenopsis geminata and wasp, however it would be interesting to demonstrate by *in-vitro* study the specific allergens and offer such reactivity.

Reactions to ant hypersensitivity can be divided into immediate (<24 hours) and delayed-type hypersensitivity reactions (>24 hours). Immediate reactions include normal local reactions (pain, swelling, erythema, heat, and characteristic pustules at sting sites (88-96%), large local reactions (a reaction larger than 10 cm), generalized cutaneous reactions (pruritus and urticaria), and systemic reactions (anaphylaxis in about 2% of cases). Delayed reactions usually occur more than 24 hours after ant stings and includes dermatitis, serum sickness, renal abnormalities, and vasculitis [14, 15]. Typically it is considered more dangerous the bites of S. Invicta but perhaps this is the result of a greater study and a better epidemiological control over it, since several deaths derived from ant stings have been reported in Mexico, in which the species involved has never been specified, and have been in areas where there are no reports of S. Invicta and instead where the species of S. Geminata is reported as native. Several cases of anaphylaxis to S. Geminata have been reported [14,15].

The diagnosis of Hymenoptera venom allergy comprises the past medical history of a systemic sting reaction, a positive *in vivo* test, and/or a positive *in vitro* test. Identification of the causative ant should be determined by an entomological specialist. The skin test is the first line *in vivo* test to diagnose fire ant-sting hypersensivity and is perfomed using fire ant Whole Body Extract (WBE) using a 1:1000 (w/v) concentration of fire ant WBE. In the case of a negative result, an intradermal skin test using concentrations of 1:1,000,000 to 1:1000 (w/v) of the fire ant WBE should be performed. All the studies showed that the use of whole body extract (WBE) surpasses the use of specific allergen skin tests. In the case of having well-defined allergens (Solenopsis Invicta), *in-vitro* tests have a lower sensitivity than in the use of skin tests and is only recommended when skin testing is negative or cannot be done or interpreted, but in the context of Tropical Fire Ant (Solenopsis Geminata) there is no standardization on their allergenic proteins and major allergens [16].

In the case of great clinical suspicion but negative skin tests and *in vitro* test the use of ant-sting challenge testis reserved, which must be performed under strict surveillance by a specialist an allergist. The initial treatment for local reactions should be local wound care, including wound dressing, topical or systemic antibiotics for secondary infection, cold compression to reduce local swelling, and topical corticosteroids to limit the swelling of large local reactions. The preventive treatment includes an epinephrine auto-injector which should be prescribed for patients with histories of severe allergic reactions. For patients with anaphylactic reactions to Hymenoptera venom, or patients who cannot avoid future exposures, the only causative treatment which reduces the risk of subsequent systemic reactions is venom immunotherapy (VIT) with a protection rate ranging from 75 to 98%, being the only mode of immunotherapy currently approved is subcutaneous (SCIT). The IFACS study demonstrated that IFA SCIT is safe and that SRs that do occur tend to be mild [17,18].

The dosing schedule for imported fire ant immunotherapy is not uniform because of the induction phase. By far the most commonly used in the United States are “conventional” (traditional, slow) regimens, giving 1 dose every week for 4 to 6 months with most expert recommendation protocols indicating treatment once or twice weekly until a maintenance dose is reached. A maintenance dose of 0.5 ml of 1:100 (w/v) imported fire ant WBE is recommended. Only in cases of endemic areas with a high incidence of fire ant stings the rush scheme is preferred, however its effectiveness has only been described in cases of imported fire ant (Solenopsis Invicta) where Imported fire ant immunotherapy can be advanced to the maintenance phase within only 1-2 days by rush protocol. The duration of immunotherapy remains unsettled; however, a usual duration is preferred to other schemes (3-5 years) or until negative skin tests are achieved [19].

Conclusion

In the world of medicine, it is sometimes forgotten that diseases and treatments must be regionalized and individualized. In Mexico, the ants that most frequently cause a hypersensitivity resection are Solenopsis Geminata (Tropical Fire Ant), the Pogonomyrmex (Harvester ant) and the Camponatus (Carpenter Ant). We demonstrated a successful subcutaneous immunotherapy scheme for Geminata solenopsis using whole body extract, using a conventional scheme, completed up to 3 years. The patient has been able to

continue her normal daily activities and is asymptomatic. Future studies and research are needed to delimit the role of immunotherapy in Solenopsis Geminata, as well as a better epidemiological study in Mexico and future research on its specific allergen proteins to be able to study *in vitro* tests. The role of cross-reactivity with solenopsis invicta and wasps should also have to be studied. It is the first reported case of immunotherapy towards Solenopsis Geminata.

Conflict of Interest

None declared.

Funding

None declared.

References

1. Rutcharin P, Raweerat S. Ant allergens and hypersensitivity reactions in response to ant stings. Asian Pac J Allergy Immunol 2015; 33: 267-275.
2. Vásquez BM. Lista de especies de hormigas (Hymenoptera: Formicidae) para México. Dugesiana. 2011; 18: 95-133.
3. Rios CL. Biodiversidad de hormigas en México, Revista Mexicana de Biodiversidad, Supl. 2014; 85: S392-S398.
4. Klotz JH, deShazo RD, Pinnas JL et al. Adverse reactions to ants other than imported fire ants. Ann Allergy Asthma Immunol. 2005; 95: 418-425.
5. Antweb last research: 16.02.2018; [http://www.antweb.org].
6. Hoffman DR. Fire ant allergy. Allergy 1995; 50: 535-544.
7. Ollert M, Blank S. Anaphylaxis to insect venom allergens: Role of molecular diagnostics. Curr Allergy Asthma Rep 2015; 15: 26.
8. Potiwat R, Tanyaratsrisakul S, Maneewatchararangsri S. Solenopsis geminata (tropical fire ant) anaphylaxis among Thai patients: Its allergens and specific IgE-reactivity. Asian Pac J Allergy Immunol.
9. Golden DBK, Moffitt J, Nicklas RA, et al. Stinging insect hypersensitivity: A practice parameter update 2011. J Allergy Clin Immunol 2011; 127: 852-854e1-23.
10. Dhami S, Nurmatov U, Varga EM, et al. Allergen immunotherapy for insect venom allergy: Protocol for a systematic review. Clin Transl Allergy 2016; 6: 6.
11. Flores RLF, Valdez LF, Bedolla BM. Prevalencia de sensibilización alérgica a abeja, mosco y hormiga roja en niños con enfermedades alérgicas. Revista Alergia México 2015; 62: 182-188.
12. Touchard A, Aili SR, Fox EGP, et al. The biochemical toxin arsenal from ant venoms. Toxins 2016; 8: 30.
13. Sukprasert S, Uawonggul N, Jamjanya T et al. Characterization of the allergen Sol gem 2 from the fire ant venom, Solenopsis geminata. J Venom Anim Toxins inc Trop Dis 2012; 18.
14. Fernández MS, Miranda A, García GJJ, et al. Anaphylaxis caused by imported red fire ant stings in Málaga, Spain. J Investig Allergol Clin Immunol 2007; 17: 48-49.
15. Knight D, Bangs MJ. Cutaneous allergic vasculitis due to solenopsis geminata (hymenoptera: formicidae) envenomation in Indonesia. Southeast Asian J Trop Med Public Health 2007; 38; 5.
16. Bernstein IL, Li TJ, Bernstein DI, et al. Allergy diagnostic testing: An updated practice parameter. Annals Allergy Asthma Immunol 2008; 100: 3.
17. Tankersley MS, Ledford DK. Stinging insect allergy: State of the art 2015. J Allergy Clin Immunol Pract 2015; 3: 315-322.
18. La Shell MS, Calabria CW, Quinn JM. Imported fire ant field reaction and immunotherapy safety characteristics: the IFACS study. J Allergy Clin Immunol 2010; 125: 1294-1299.
19. Haymore BR, McCoy RL, Nelson MR. Imported fire ant immunotherapy prescribing patterns in a large health care system during a 17 year period. Ann Allergy Asthma Immunol 2009; 102: 422-425.

This manuscript was peer-reviewed
Mode of Review: Single-blinded
Academic Editor: Dr. Carlos Polanco