Medical Case Reports Journal

Available Online: https://mcrj.edwiserinternational.com

Case Report on Acute Bacterial Mediastinitis and its Management through Videothoracoscopic Surgery

Guntug Batihan, Ozan Usluer and Seyda Ors Kaya*

Dr Suat Seren Chest Diseases and Surgery, Medical Practice and Research Center, Department of Thoracic Surgery, University of Health Sciences, Izmir, Turkey

Article info

Received 24 February 2019
Revised 17 April 2019
Published 22 April 2019

*Corresponding author: Guntug Batihan, Dr Suat Seren Chest Diseases and Surgery, Medical Practice and Research Center, Department of Thoracic Surgery, University of Health Sciences, Izmir, Turkey; E-mail: gbatihan@hotmail.com

Abstract

Acute bacterial mediastinitis is an uncommon but potentially life-threatening infection involving the structures of the mediastinum. Most of these infections are related to complication after median sternotomy or esophageal disruption. Surgery is an important component of treatment especially in cases of sternal dehiscence and esophageal perforations. We aim to present video thoracoscopic approach to the case of acute bacterial mediastinitis.

Keywords: Acute mediastinitis; Emphysema; Trauma; Thoracentesis; Antibiotic

Introduction

Acute mediastinitis is an uncommon but potentially life-threatening infection involving the structures of the mediastinum. It occurs most frequently as a postoperative infection after median sternotomy, but other common cause is esophageal perforation. Incidence ranging from 0.15% to >5% of all cardiothoracic operations. Staphylococci are the most common organisms found in patients with acute mediastinitis [1,2]. Early diagnosis, appropriate antibiotic therapy and surgical intervention may alter the prognosis. We report a 67-year-old man who presented with chest pain and subcutaneous emphysema.

Case Presentation

A 67-year-old man admitted to our clinic with chest pain, fever and general body weakness. Patient's history revealed that his complaints had been present for a week. He had no history of any chronical illness, trauma and surgical intervention. The patient stated that he was swallowed a fishbone 2 weeks ago.

Physical examination revealed that the left side of his neck was markedly tender and swollen, without evidence of trauma. His body temperature was 38.2°C. Laboratory analysis showed a white cell count of 17.5 × 103/µL and the inflammatory marker C-reactive protein (CRP) was 45 mg/dL.

His chest radiogram showed minimally pleural effusion on the left side. Immediate computed tomography (CT) of the chest and neck revealed generalized air bubbles in the mediastinum and left sided pleural effusion (Figure 1).

Patient was diagnosed as acute mediastinitis and systemic antibiotic therapy was started. Thoracentesis was applied to the patient and purulent fluid was aspirated from the left side, so chest drainage was planned.

To maintain debridement and drainage of the mediastinum surgical intervention was planned.

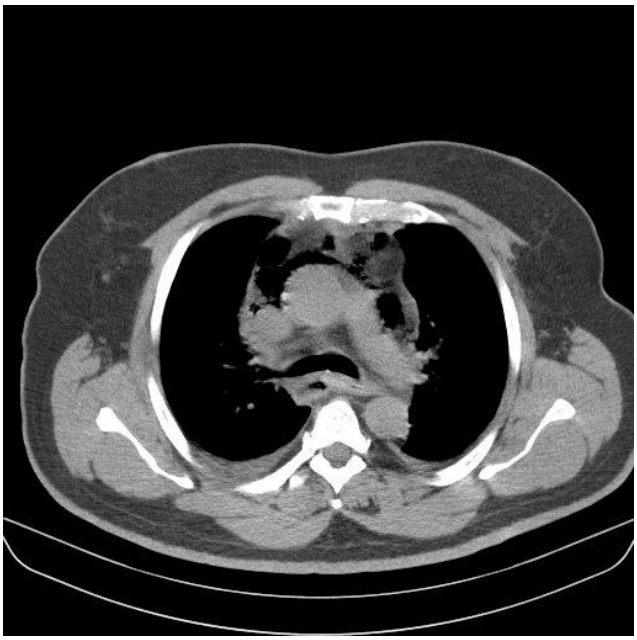

Figure 1: Generalized air bubbles in the mediastinum and bilaterally pleural effusion were seen in thorax computed tomography.

Surgical Technique

General anesthesia applied with using double lung-ventilation to achieve lung separation. In the lateral decubitus position 2.0-cm-long skin incision was made at the 5th intercostal space of the midaxillary line and right sided uniportal video thoracoscopy was applied.

Mediastinal pleura was incised, and purulent contents and necrotic tissues were removed (Figure 2 and 3) Intrapleural space irrigated with antimicrobial solutions. The pleural space was drained with one chest tube connected to underwater seal. The surgical procedure was completed without any complication.

Follow-up

Staphylococcus aureus was isolated from pleural specimens and appropriate antibiotic treatment was initiated. After surgery the patient was followed up for 2 weeks in an intensive care unit and pleural irrigation administrated through the chest tube three times daily (Figure 4). But unfortunately, patient died because of pneumonia and sepsis despite aggressive antibiotic treatment and close follow-up.

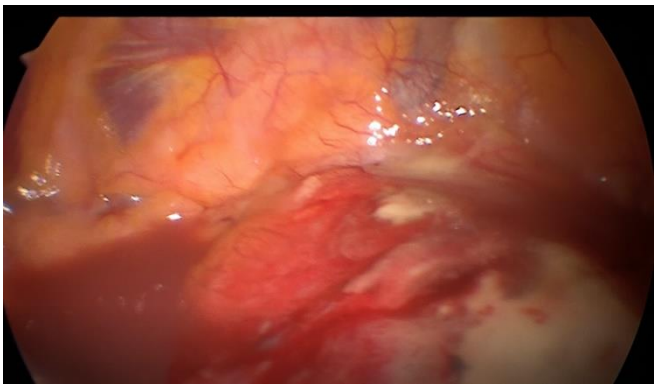

Figure 2: Peroperative image of the mediastinum. Purulent and necrotic surface of the mediastinal pleura was seen.

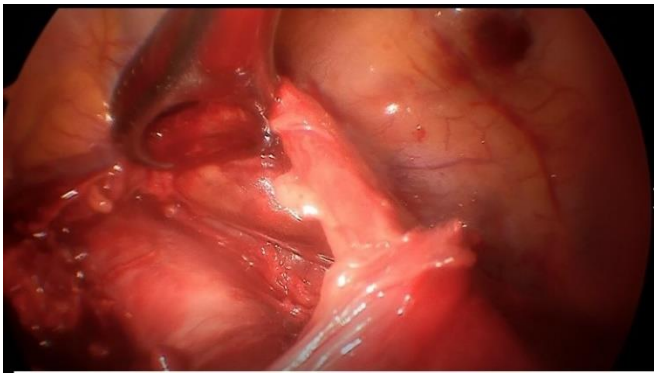

Figure 3: Mediastinal pleura was incised, and purulent contents and necrotic tissues were removed.

Figure 4: Postoperative chest radiogram revealed bilateral lower zone heterogeneous opacity.

Discussion

The great majority of mediastinal infections are originating from many sources. Most of these infections are related to complication after median sternotomy or esophageal disruption [3,4] Trauma, tracheobronchial perforation, descending infection following surgery of the head and neck and progressive odontogenic infections are other possible causes. Patients with acute mediastinitis usually present with fever, chest pain, weakness, and respiratory distress. Fever, tachycardia, crepitus, and localized swelling are often seen on physical examination in patients with acute mediastinitis. Our patient had no history of any chronical illness, odontogenic infection, trauma and surgical intervention. The history of swallowing a fishbone may explain the occurrence of acute bacterial mediastinitis but we have no evidence for the fishbone perforating the esophagus.

Systemic antimicrobials therapy and surgical debridement and drainage are the main components of treatment. In literature, acute mediastinitis mortality has been reported to range from 15.4% to 50% [4]. Early diagnosis, appropriate antibiotic therapy and surgical intervention may alter the prognosis.

There are few cases of acute bacterial mediastinitis as complication of a swallowed fish bone in literature but spontaneous bacterial mediastinitis is extremely rare [5].

Surgery is an important component of treatment especially in cases of sternal dehiscence and esophageal perforations [6]. Video thoracoscopic surgery would also apply to drainage of the mediastinum and debridement of necrotic tissue.

Conclusion

Acute bacterial mediastinitis is a life-threatening infection. Early diagnosis and serial transcervical and transthoracic operative drainage and debridement would reduce the excessive mortality. Broad spectrum antibiotic therapy should be initiated immediately, and it should be tailored according to the culture-antibiogram results. If the surgical approach is needed, less invasive but effective procedures like video thoracoscopic surgery should be preferred.

Conflict of Interest

None declared.

Funding

None declared.

References

1. Macrí P, Jiménez MF, Novoa N, et al. Descriptive of a series of patients diagnosed with acute mediastinitis. Arch Bronconeumol 2003; 39: 428-430.
2. Salo JA, Isolauri JO, Heikkila LJ, et al. Management of delayed esophageal perforation with mediastinal sepsis. Esophagectomy or primary repair? J Thorac Cardiovasc Surg 1993; 106: 1088-1091.
3. Enquist RW, Blanck RR, Butler RH. Nontraumatic mediastinitis. JAMA 1976; 236: 1048-1049.
4. Fatureto MC, Junior MA, Santana TC. Acute mediastinitis: Restropective analysis of 21 cases. J Bras Pneumol 2005; 31: 307-311
5. Katsetos MC, Tagbo AC, Lindberg MP, et al. Esophageal perforation and mediastinitis from fish bone ingestion. South Med J. 2003; 96: 516-520.
6. Schroeyers P, Wellens F, Degrieck I, et al. Aggressive primary treatment for poststernotomy acute mediastinitis: our experience with omental and muscle flap surgery. Eur J Cardiothorac Surg 2001; 20: 743-746.

This manuscript was peer-reviewed
Mode of Review: Single-blinded
Academic Editor: Dr. Ruqaiyah Saleem